

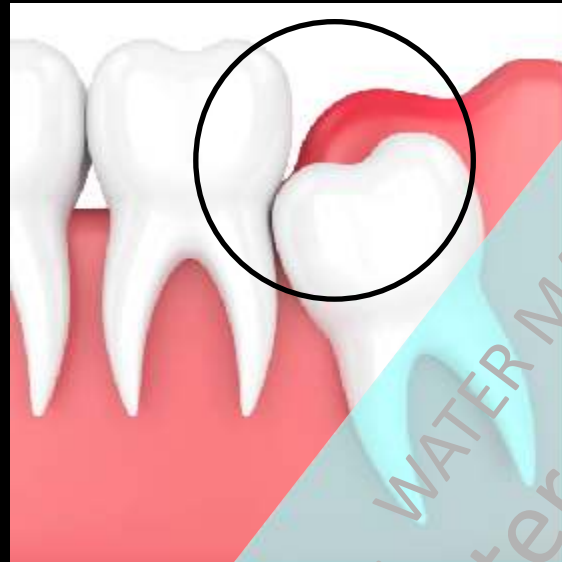# Some oral problems which requires Immediate Dental consultation

## Pericoronitis

Pericoronitis is the infection and inflammation of the gums surrounding or overlying an erupting or impacted tooth.

This condition is most commonly associated with the eruption of lower third molars (Wisdom tooth)

Gingiva around the crown is red, swollen, and painful.



## Herpes simplex virus infections

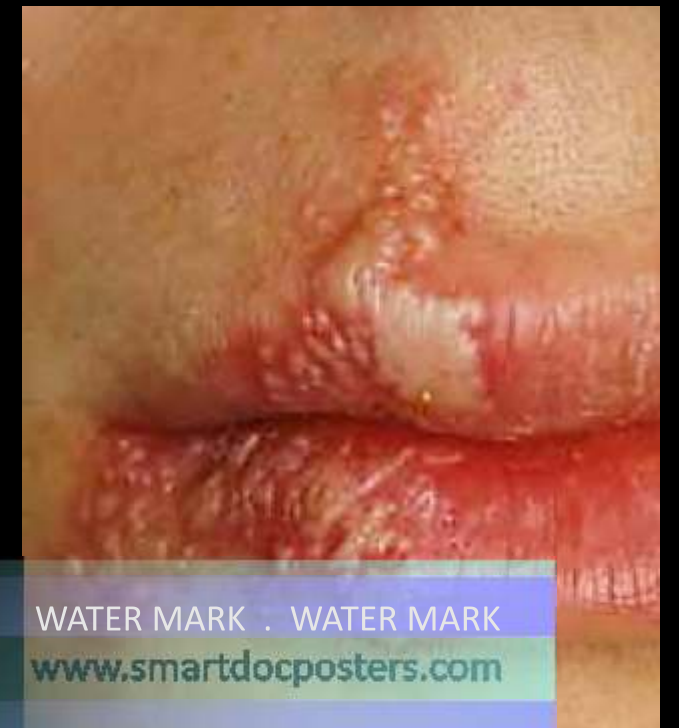Recurrent small blisters on the lips and palatal mucosa.

The symptoms are :

Redness, swelling, pain or itching may develop in the area of the infection.

Painful, fluid-filled blisters may appear on the lips or under the nose.

The blisters will leak fluid and become sores.



YOUR CLINIC DETAILS WILL BE ADDED HERE

# Some oral problems which requires Immediate Dental consultation

## Candidiasis (Oral Thrush)

Infection with Candida fungus species is known as candidiasis.

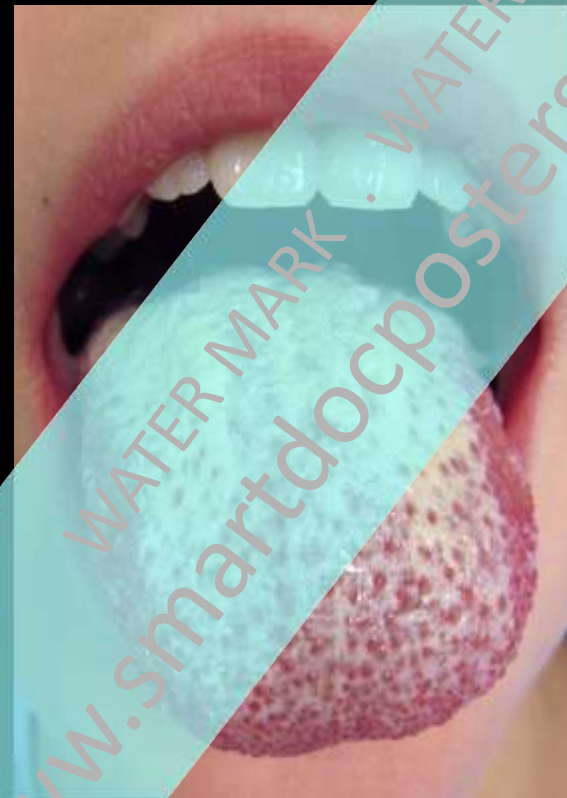The symptoms are :

White patches in the mouth that can often be wiped off, leaving behind red areas that may bleed slightly.

Loss of taste or an unpleasant taste in the mouth.

Redness inside the mouth and throat.

A painful, burning sensation in the mouth.

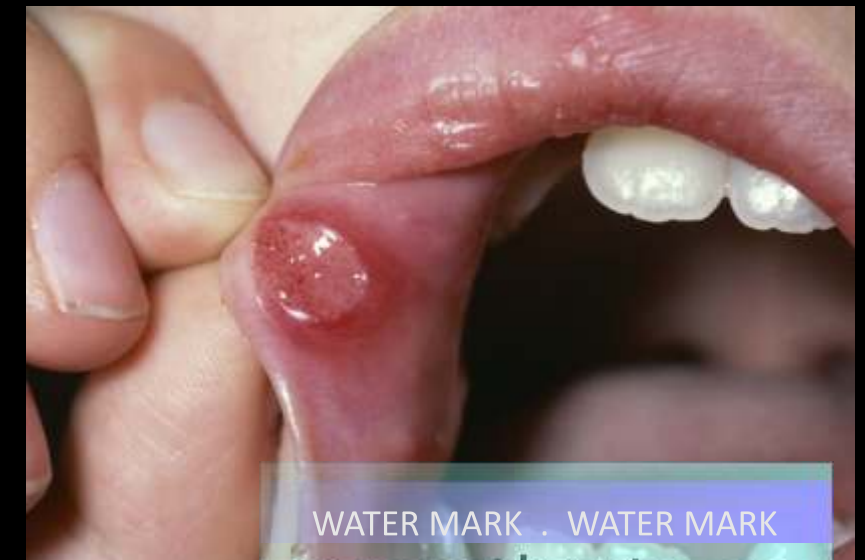

## Aphthous ulcer

This is one of the most common oral diseases.

They are painful ulcers ranging in size from less than 1 mm to 2 centimeters.

They may appear as single or multiple.



YOUR CLINIC DETAILS WILL BE ADDED HERE

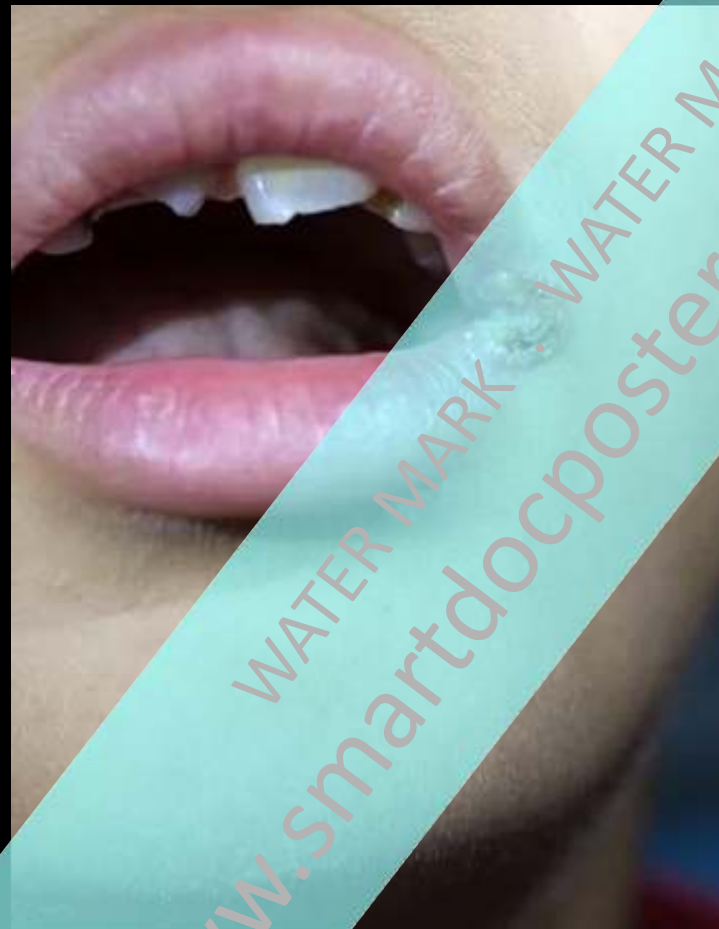

# Some oral problems which requires Immediate Dental consultation

## Angular cheilosis

Angular cheilosis begins as a patch of dry, cracked skin at one or both corners of the mouth.

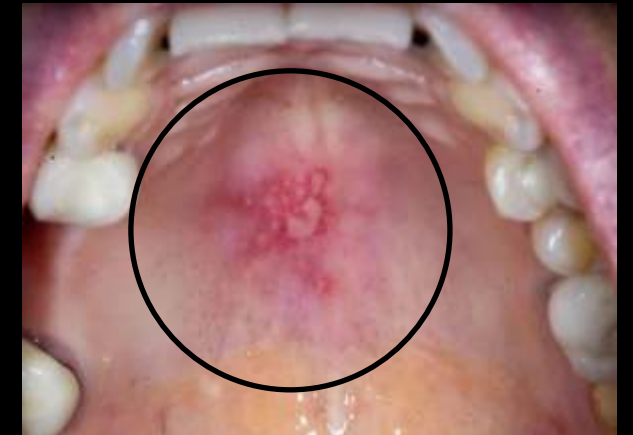
If it's not treated early, it can progress into swollen, painful sores that may bleed when you open your mouth.



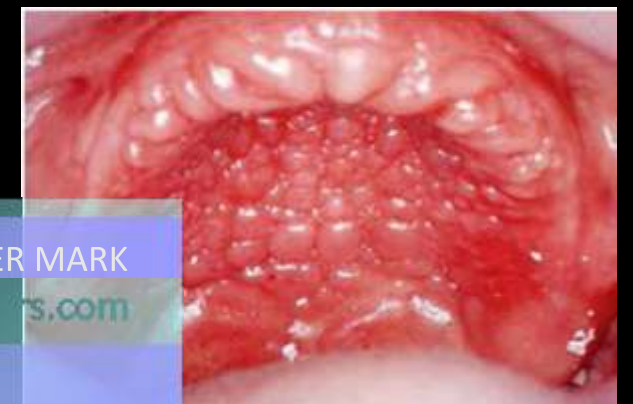## Denture sore mouth

Related to the wearing of Dentures.

The mildest form of denture sore mouth appears as small red spots on the posterior palatal mucosa.



As the condition worsens, large areas turn crimson red .

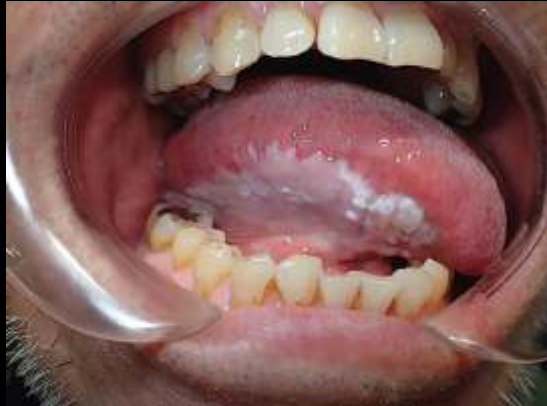

YOUR CLINIC DETAILS WILL BE ADDED HERE

# ORAL PRE-CANCEROUS LESIONS

Having increased potential of becoming cancerous !

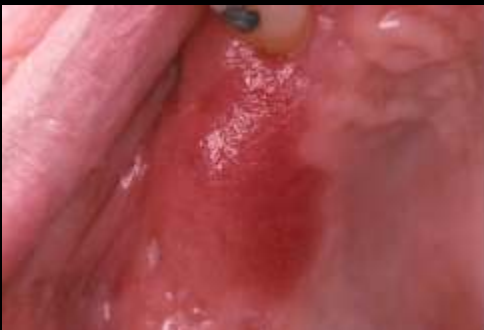## Leukoplakia



Leukoplakia is a condition seen as white patches on the tongue, gums or the inside of the cheeks.

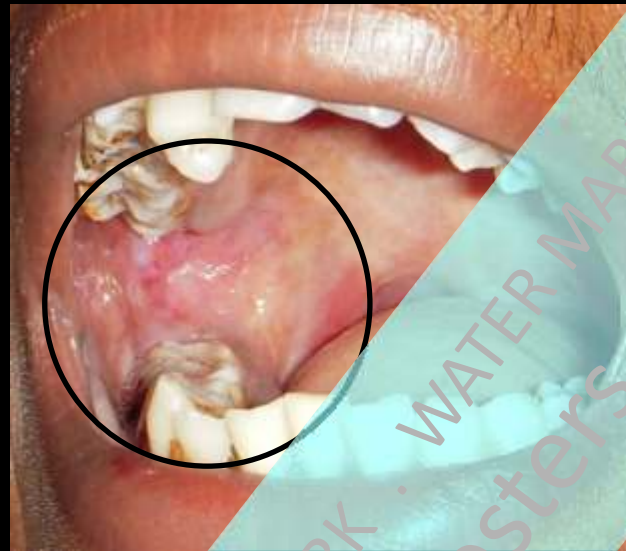The patches are not painful .

## Erythroplakia



A fiery red patch ,  
Most commonly seen in the soft palate, the floor of the mouth, and buccal mucosa.

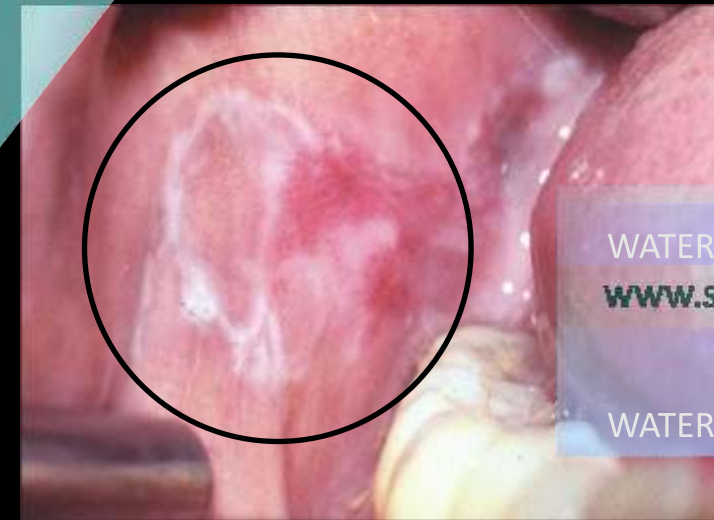
## Submucous fibrosis



Oral submucous fibrosis, is characterized by inflammation and progressive fibrosis of the submucosal tissues.

There is stiffness of oral mucosa,  
Inability to open the mouth  
And inability to eat .

## Lichen planus




Oral lichen planus is an inflammatory condition that affects mucous membranes inside the mouth.

They appear as white, lacy patches or red, swollen tissues; or open sores.

These lesions may cause burning pain or other discomfort.

YOUR CLINIC DETAILS WILL BE ADDED HERE

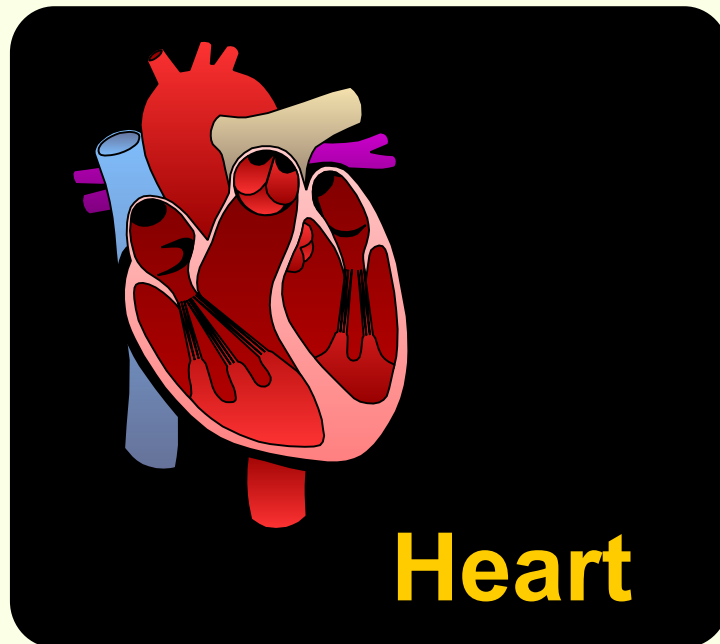




# Untreated dental problems... Can lead to damage of various body organs !

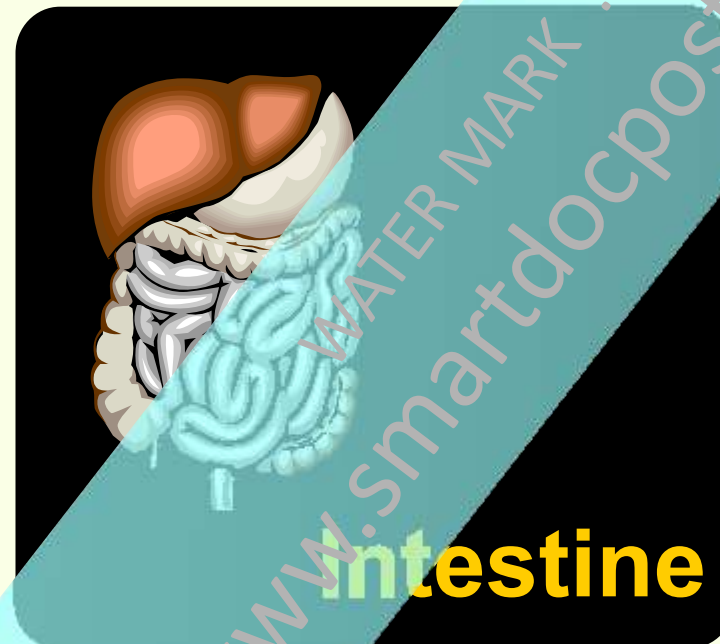From oral infections, especially gum disease, the bacteria enters the blood stream and are transported to various body organs .

This can cause ...



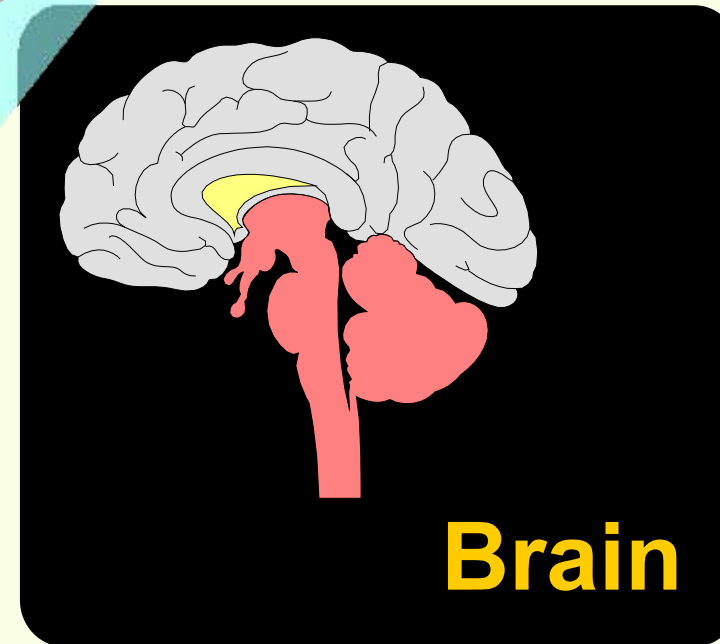
**Heart**

**Heart disease**



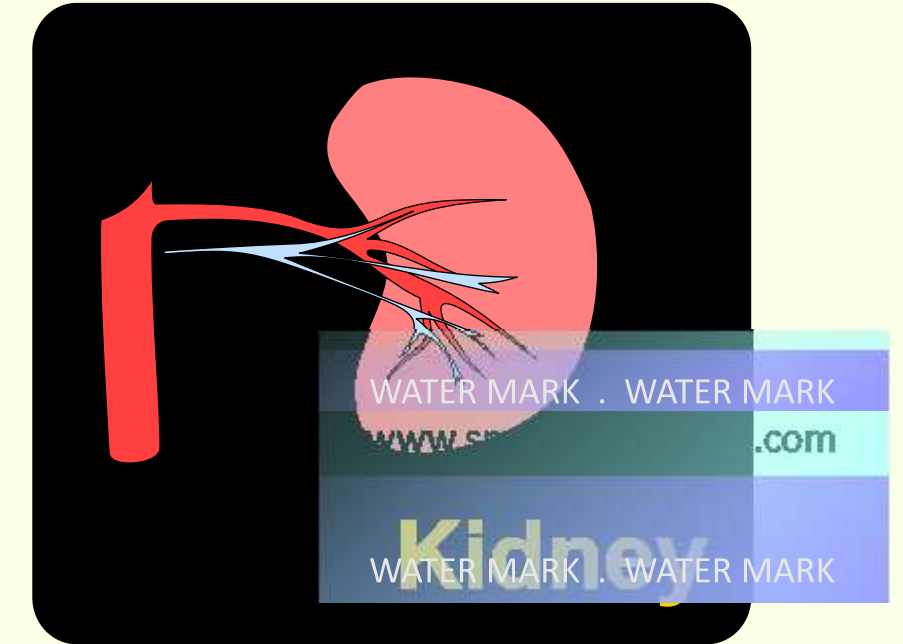
**Intestine**

**Stomach problems**



**Brain**

**Damage to the brain**



**Kidney**

**Kidney problems**

**YOUR CLINIC DETAILS WILL BE ADDED HERE**



# Dental care During Pregnancy

1

Frequent dental check-up at least once in 2 months - to avoid infections which can affect the foetus.



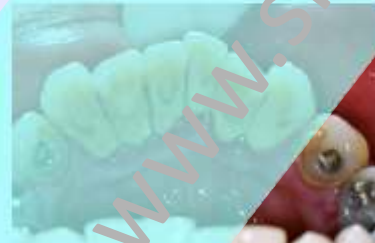2



Brush twice daily and floss before going to bed.

3

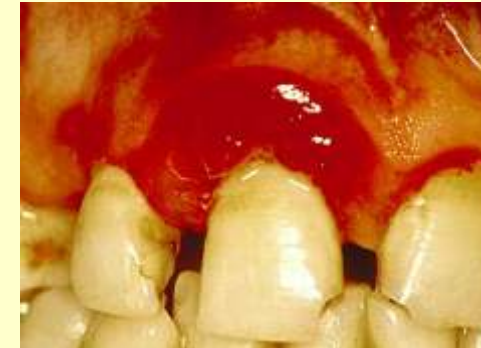Professional teeth cleaning (scaling) for removal of calculus deposits!



calculus deposits

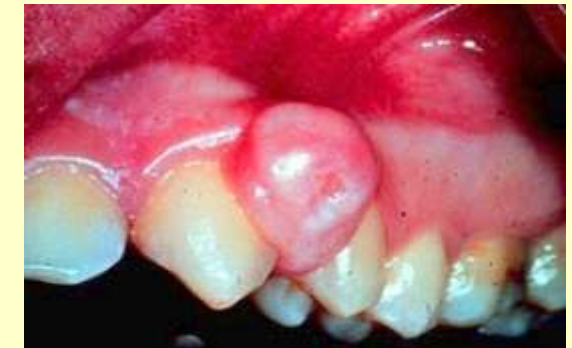## Some oral conditions during Pregnancy

Pregnancy gingivitis



Swollen red gums and bleeding while brushing may occur.

Pregnancy tumors



Painless swelling of the gums. They are not cancerous. They subside after child birth.

WATER MARK . WATER MARK  
www.smartdocposters.com

WATER MARK . WATER MARK

## Premature delivery

Excessive bacteria from oral infections can enter the blood stream and **can cause premature delivery !**

YOUR CLINIC DETAILS WILL BE ADDED HERE



# Oral Cancer

**90% of oral cancer is caused by smoking or chewing of tobacco.**



## SOME WARNING SIGNS of oral cancer

A sore that does not heal .

White or red patch in the mouth.

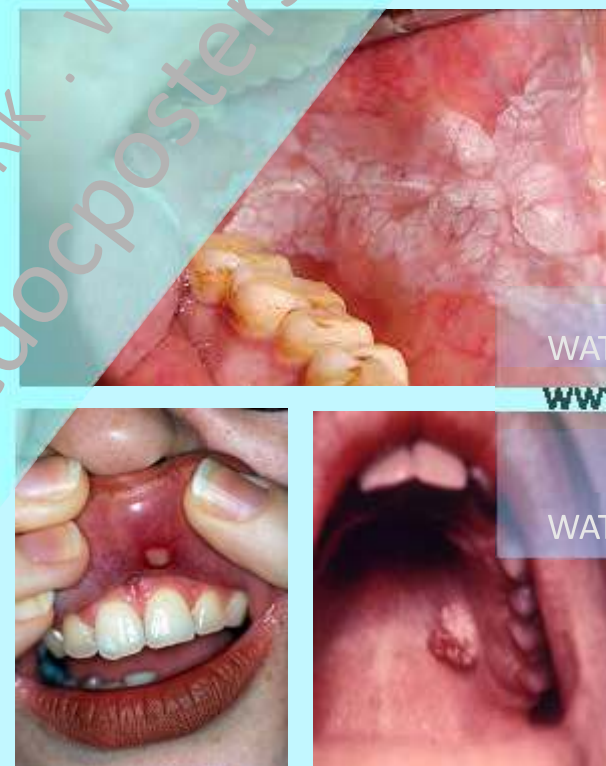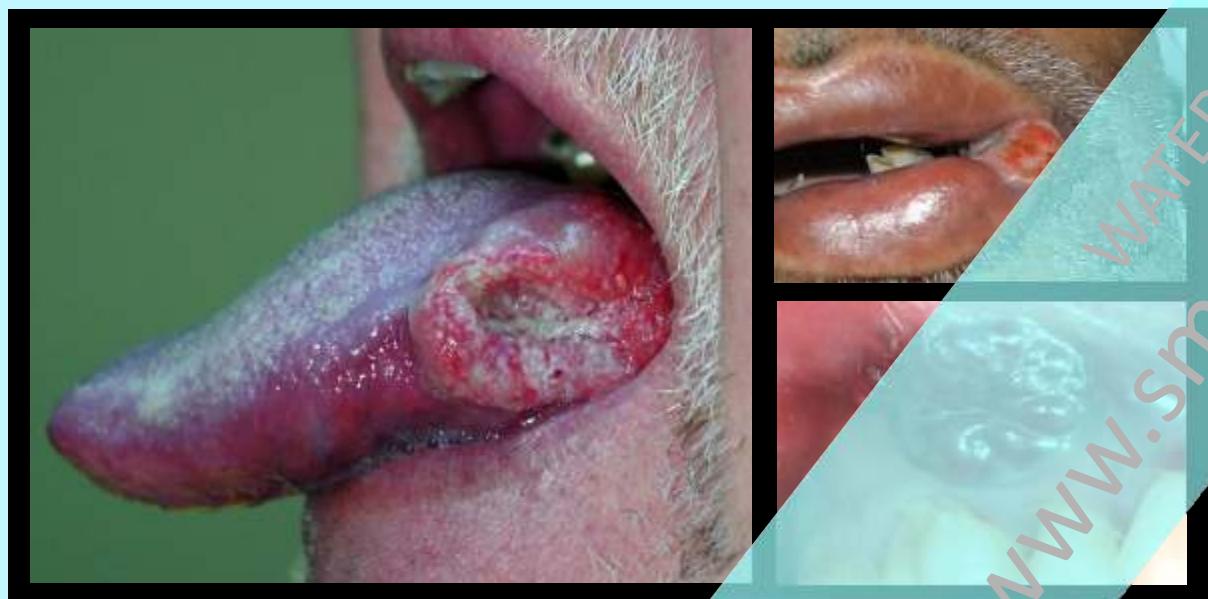Persistent swelling of the lips or gums.

Having difficulty in chewing or moving the tongue.

Change in voice.

Persistent bleeding, pain or numbness.

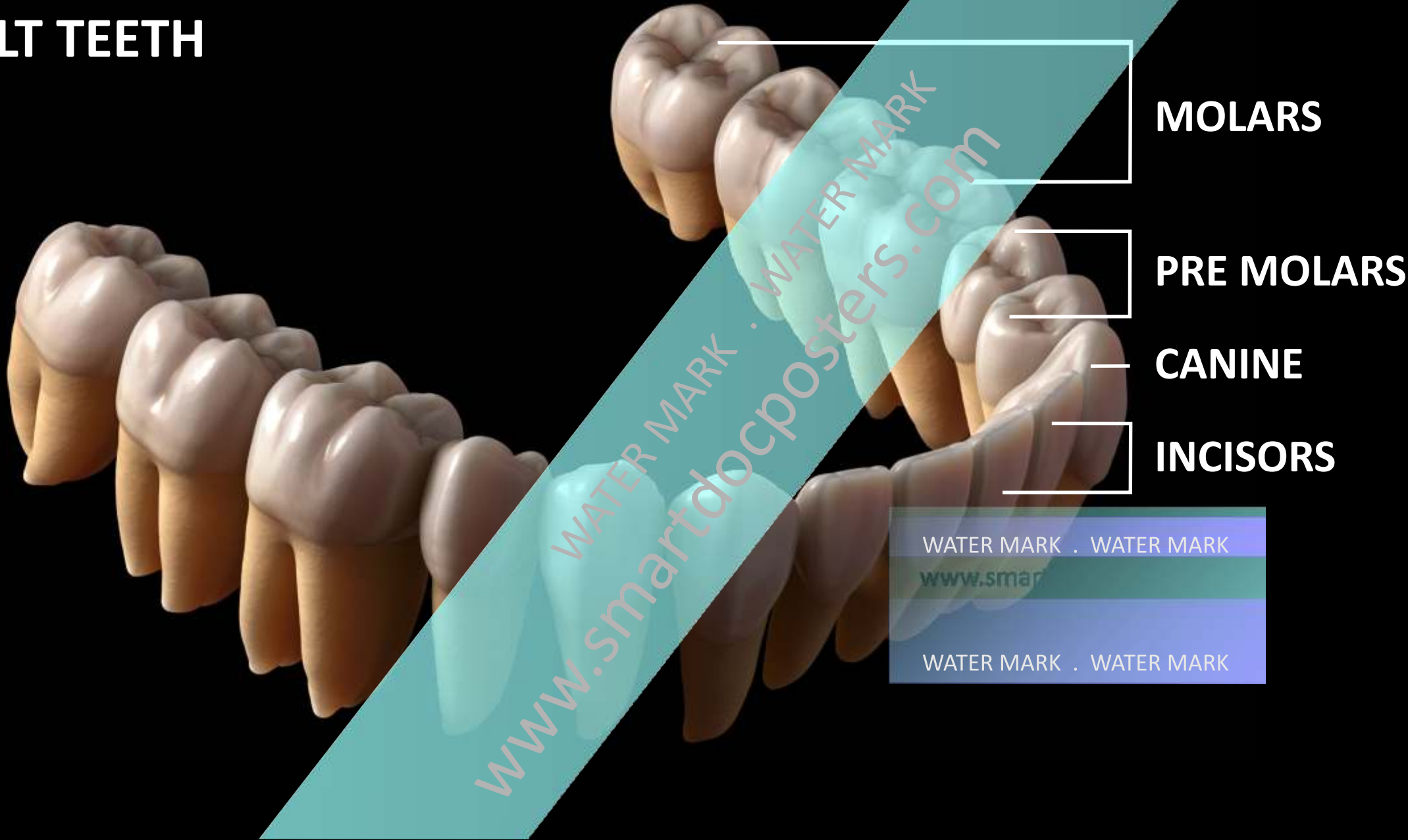
Feeling of swelling in the throat.



**YOUR CLINIC DETAILS WILL BE ADDED HERE**

# Know your teeth !

## ADULT TEETH



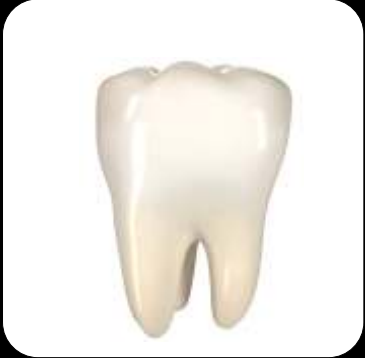INCISOR



CANINE



PRE MOLAR



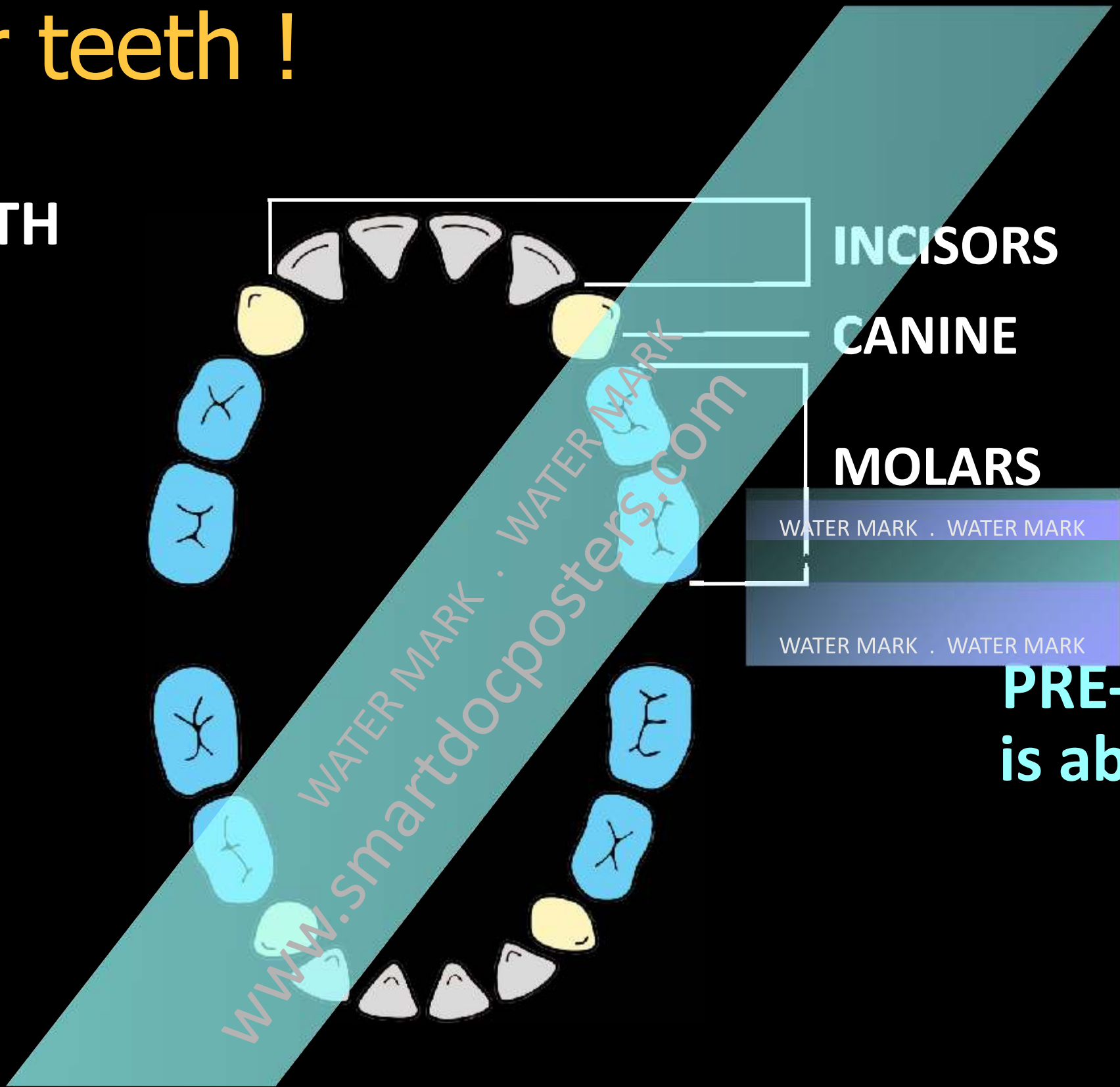
MOLAR

YOUR CLINIC DETAILS WILL BE ADDED HERE



# Know your teeth !

## PRIMARY TEETH in Children

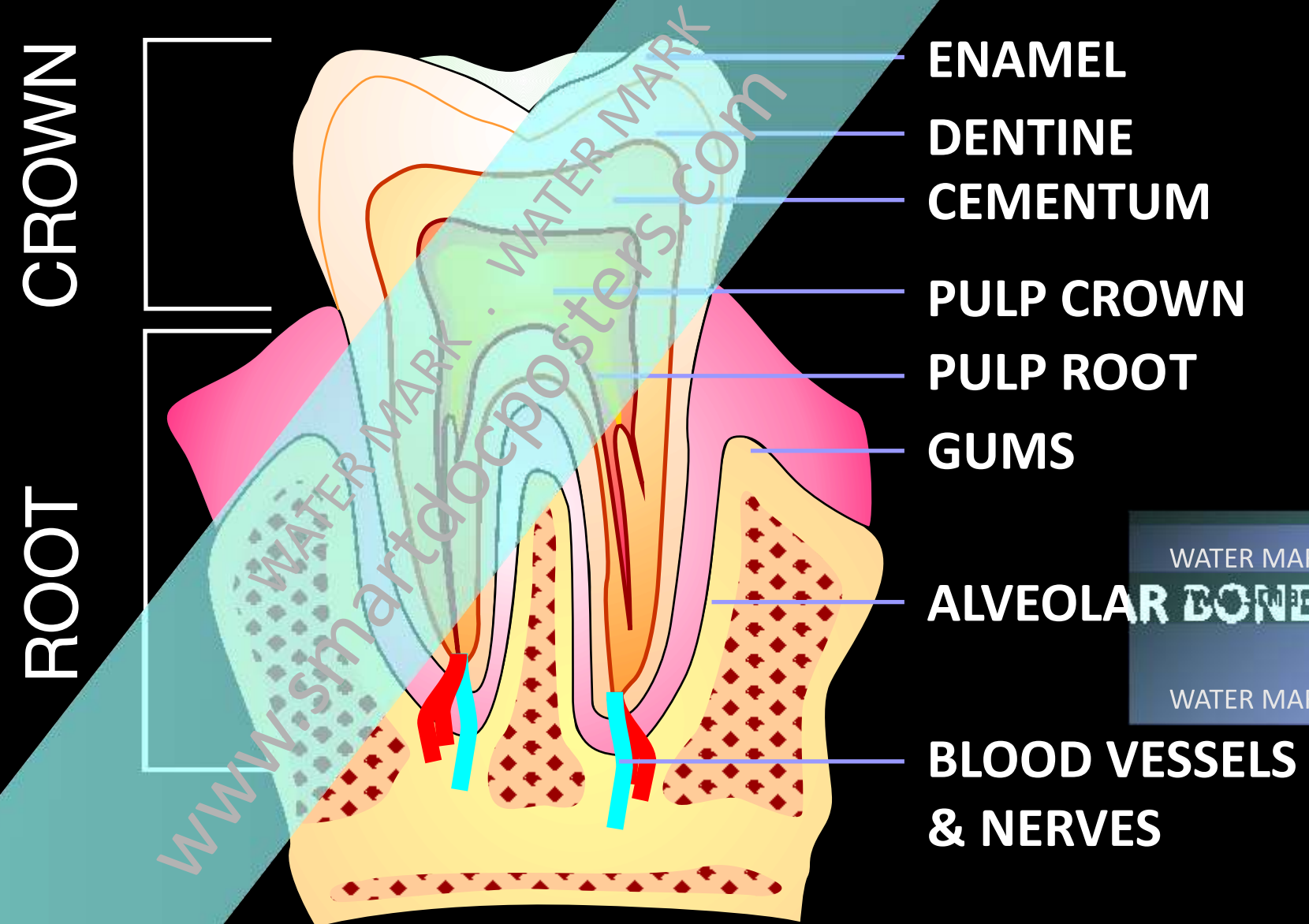


**PRE- MOLAR** teeth  
is absent in Children.

**YOUR CLINIC DETAILS WILL BE ADDED HERE**

# Know your teeth !

## TOOTH - CROSS SECTION



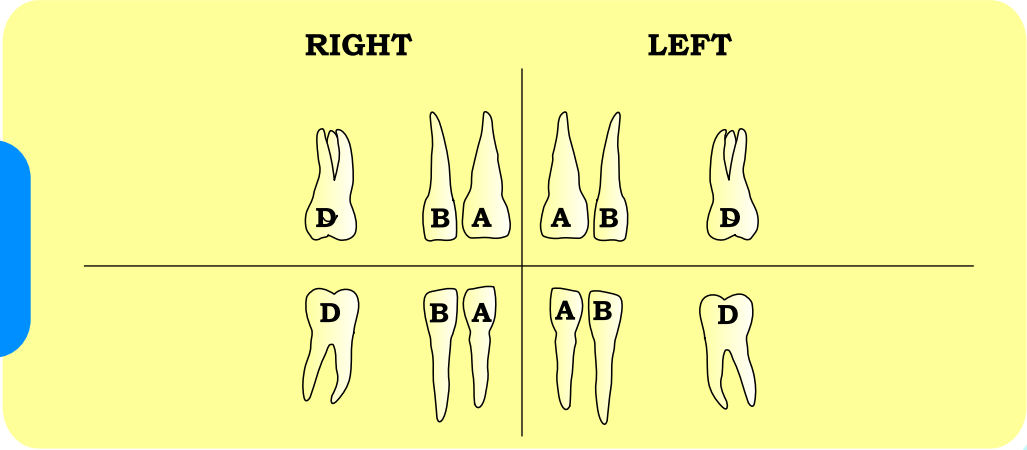
YOUR CLINIC DETAILS WILL BE ADDED HERE



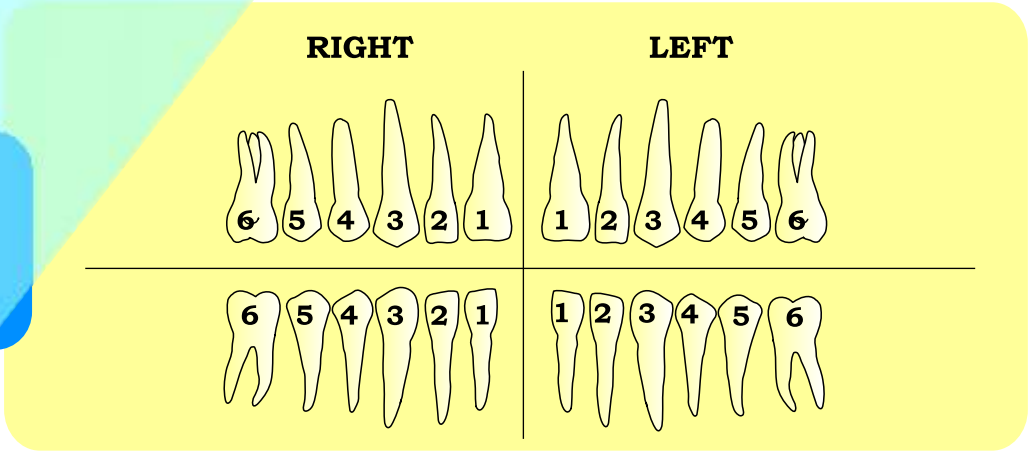
# TOOTH ERUPTION SEQUENCE

## AGE

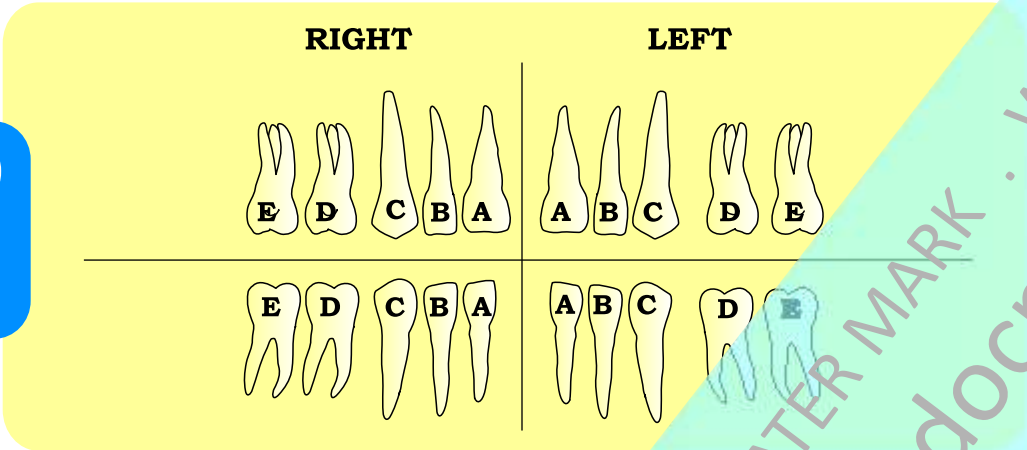
5 TO 15 MONTHS



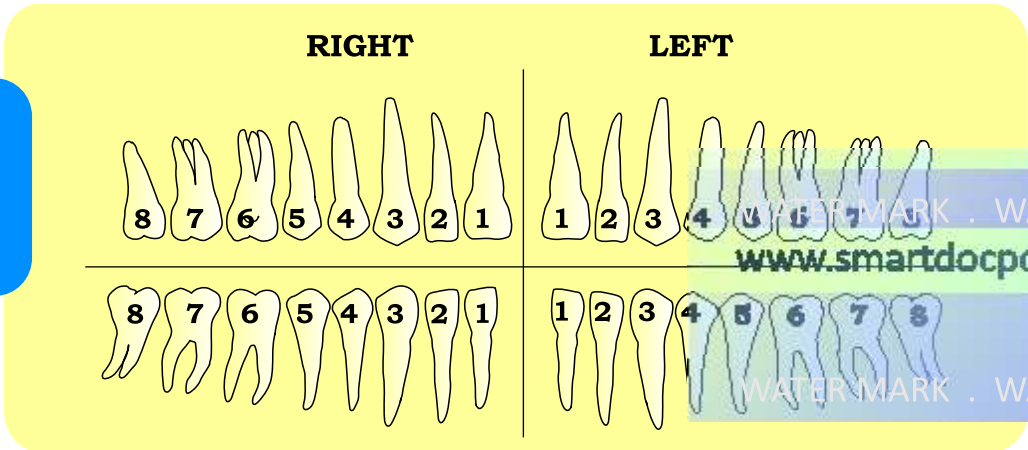
7-14 YEARS



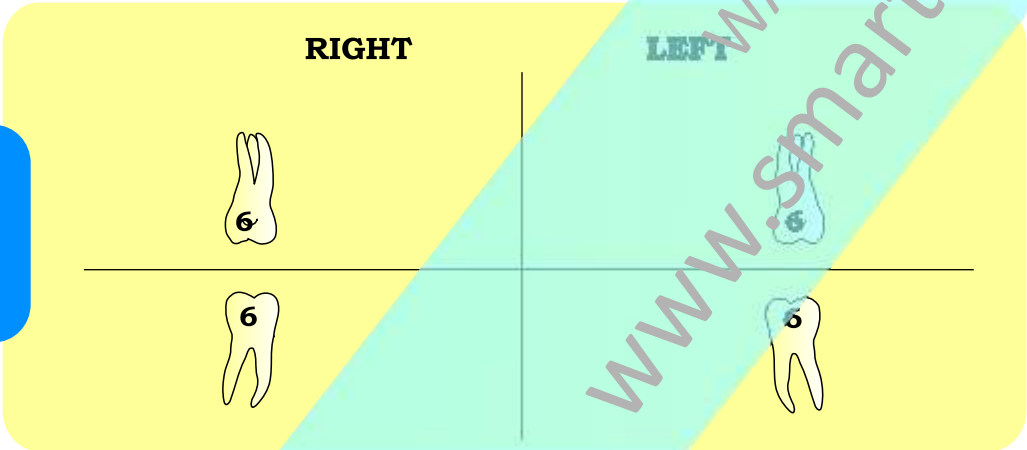
15 TO 30 MONTHS



15 - 20 YEARS



6 YEARS

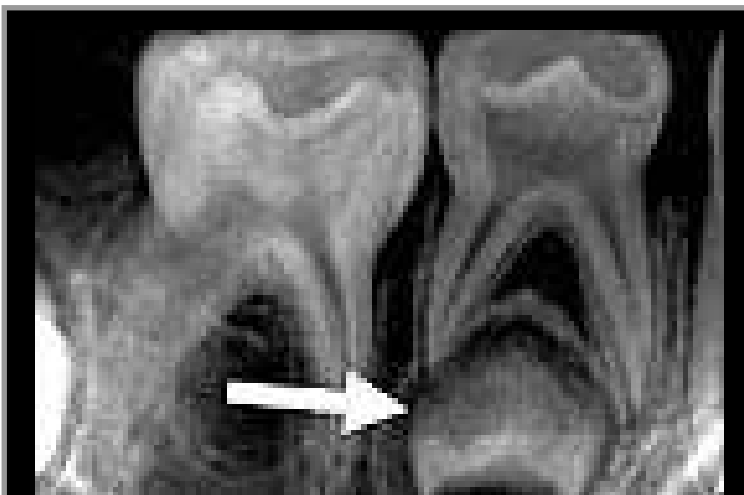

YOUR CLINIC DETAILS WILL BE ADDED HERE

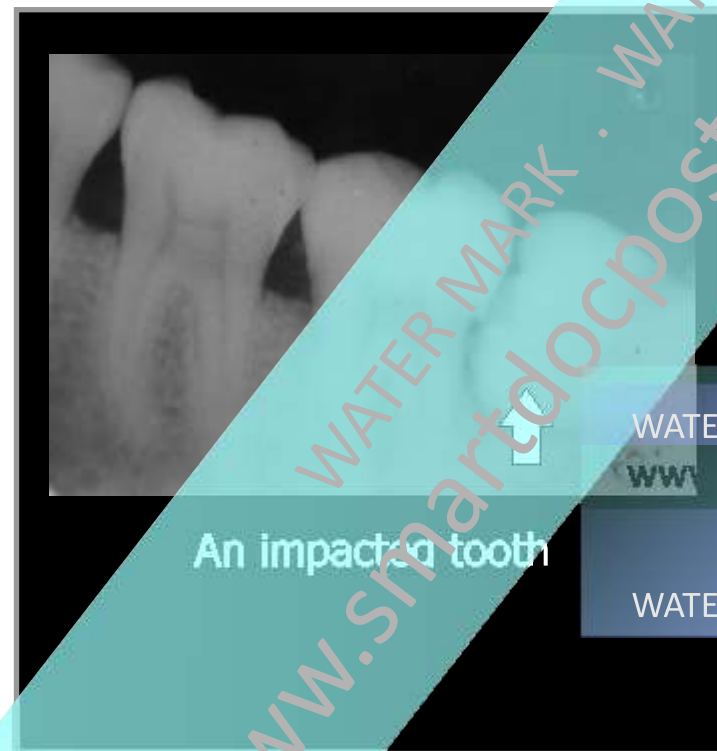

# The need to take Dental X-ray

Dental x-rays enables the Dental surgeon to determine the mode of treatment .



This is a dental x-ray showing a permanent premolar tooth erupting under a primary molar tooth in a child.



An impacted tooth

**In these conditions, Dental X-ray is a must !**

Before doing a dental filling

Before doing root canal treatment

For impacted tooth removal

For detecting bone loss in gum disease

Before doing orthodontic treatment

**YOUR CLINIC DETAILS WILL BE ADDED HERE**

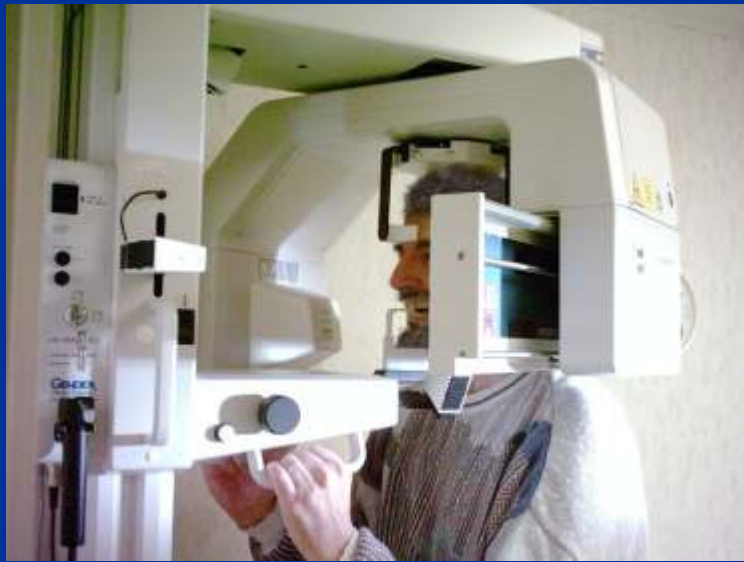

The need for taking

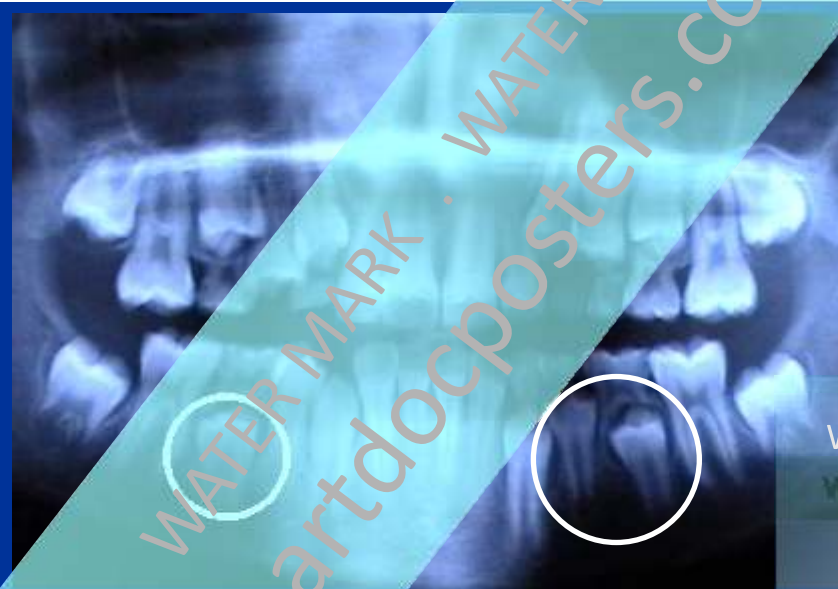
# Dental OPG

An Orthopantomogram (OPG) is a panoramic scanning Dental X-ray of the upper and lower jaw.

An OPG provides an overall view of the Jaws, Teeth, and Joints.



The O.P.G Unit



This is the dental opg of mixed dentition having both primary and permanent teeth. Here the erupting permanent teeth can be seen.

## When a **Dental OPG** Should be taken ?

To get an idea about teeth eruption pattern & jaw growth.

Before doing orthodontic treatment to correct malalignment of teeth.

To find out bone loss in cases of severe gum disease.

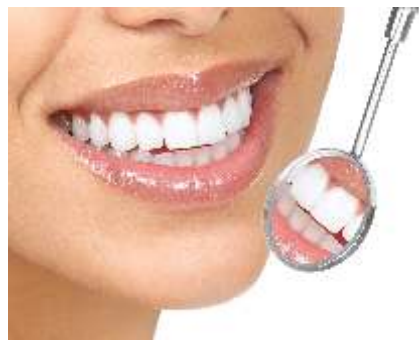For removal of impacted teeth.

For doing multiple root canal treatment.

For placement of dental implants

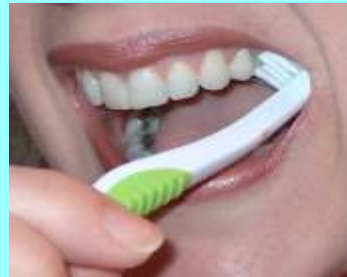For diagnosing jaw fracture .

**YOUR CLINIC DETAILS WILL BE ADDED HERE**



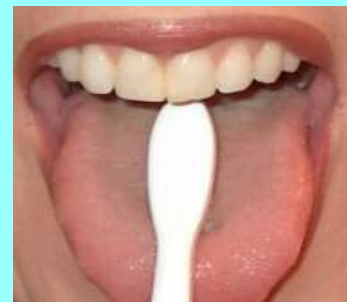# For good oral health

## Brushing



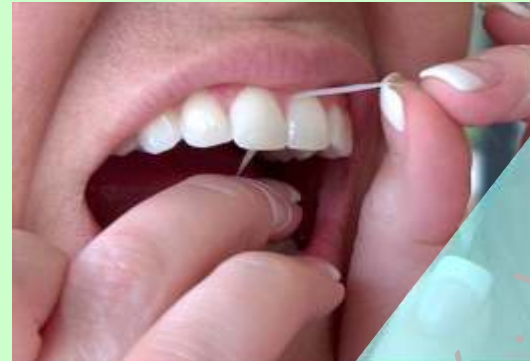**Brush twice a day.**

**Brush at night before going to bed.**



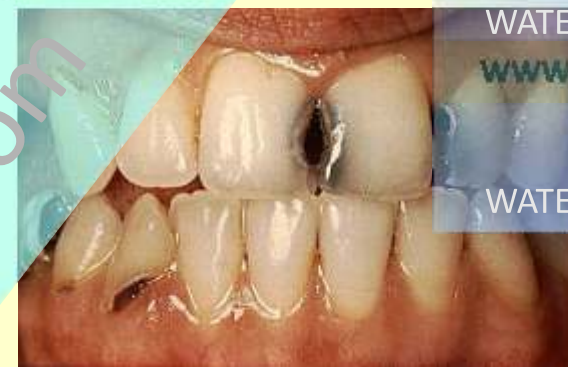**Also remember to brush your tongue.**

## Flossing



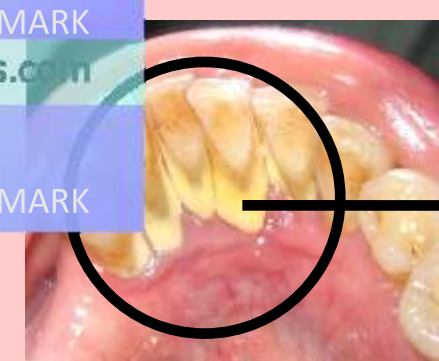
**Food particles which gets stuck in between the teeth and cannot be removed by brushing, must be removed by FLOSSING.**

## Dental fillings



**Get Tooth cavities filled at the earliest .**

## Ultrasonic teeth cleaning



**Calculus deposits**

**Calculus deposits cause bad breath, gum disease and tooth loss. Ultrasonic cleaning should be done to remove these Calculus deposits.**

# Do Dental checkup every 6 months

**YOUR CLINIC DETAILS WILL BE ADDED HERE**



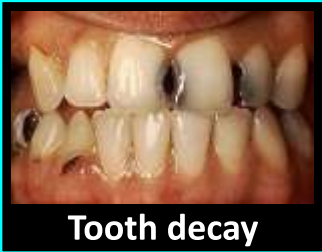# Activities that ruin your Beautiful Smile

## 1 Soft drinks



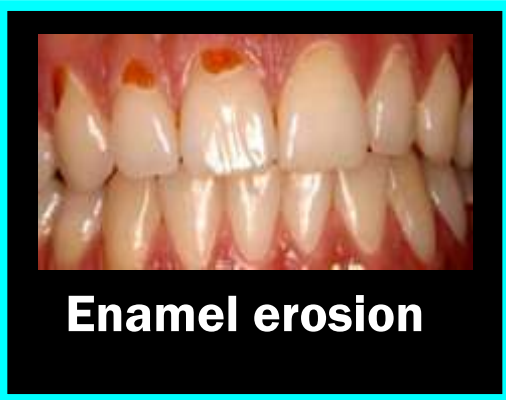Frequent use of soft drinks lead to **TOOTH EROSION** due to the high concentration acidic components , which wear away the tooth enamel.

The sugar in the soft drinks causes **TOOTH DECAY & GUM DISEASE.**

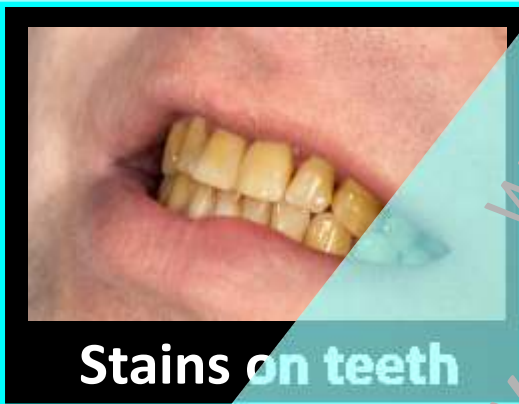

Tooth decay

Dark colour in the soft drinks **STAINS YOUR TEETH.**



Enamel erosion

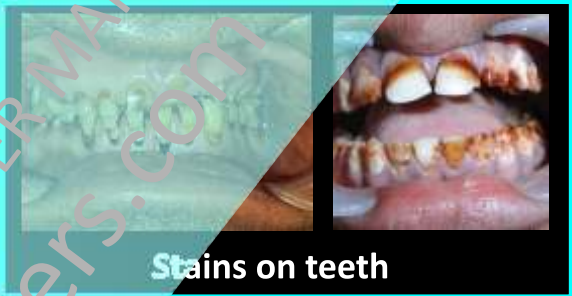

Stains on teeth

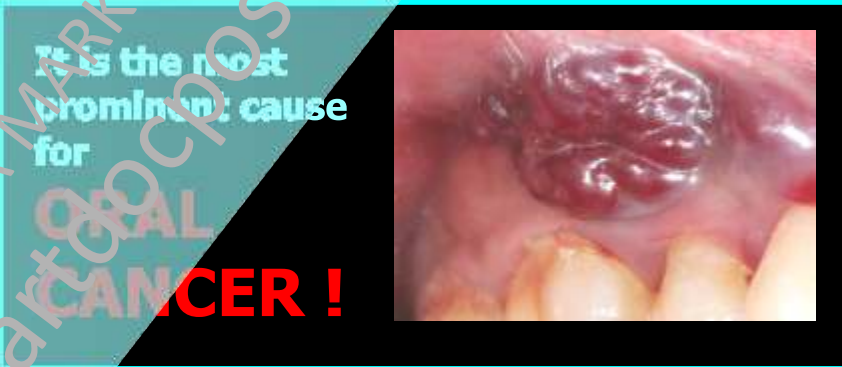## 2 Smoking / Tobacco chewing



Smoking and Tobacco chewing **STAINS YOUR TEETH !**



Stains on teeth

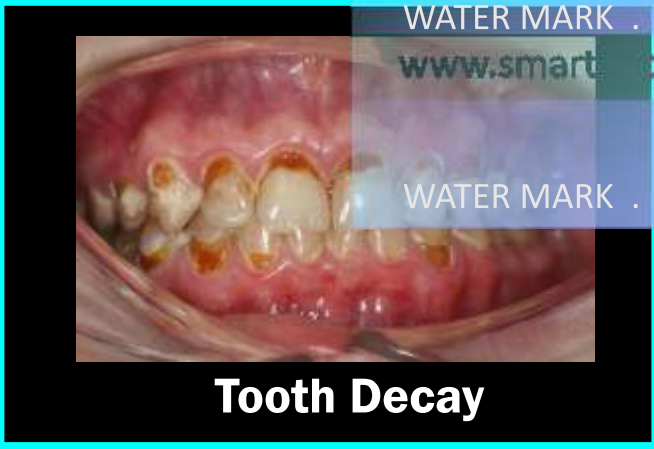

It is the most prominent cause for **ORAL CANCER !**

## 3 Sticky candies



Frequent use of sticky candies and improper brushing causes **TOOTH DECAY .**



Tooth Decay

YOUR CLINIC DETAILS WILL BE ADDED HERE