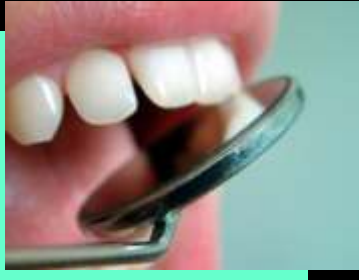
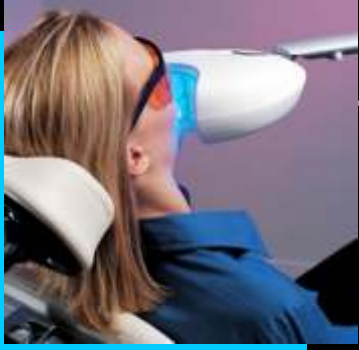
DENTAL TREATMENT
PATIENT EDUCATION MANUAL



IMAGES
&
ILLUSTRATION
FOR
PATIENT
EDUCATION

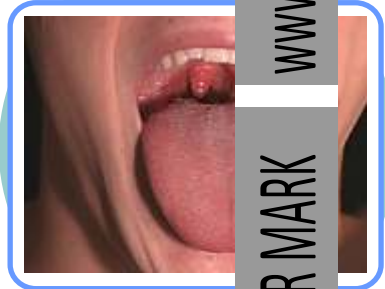
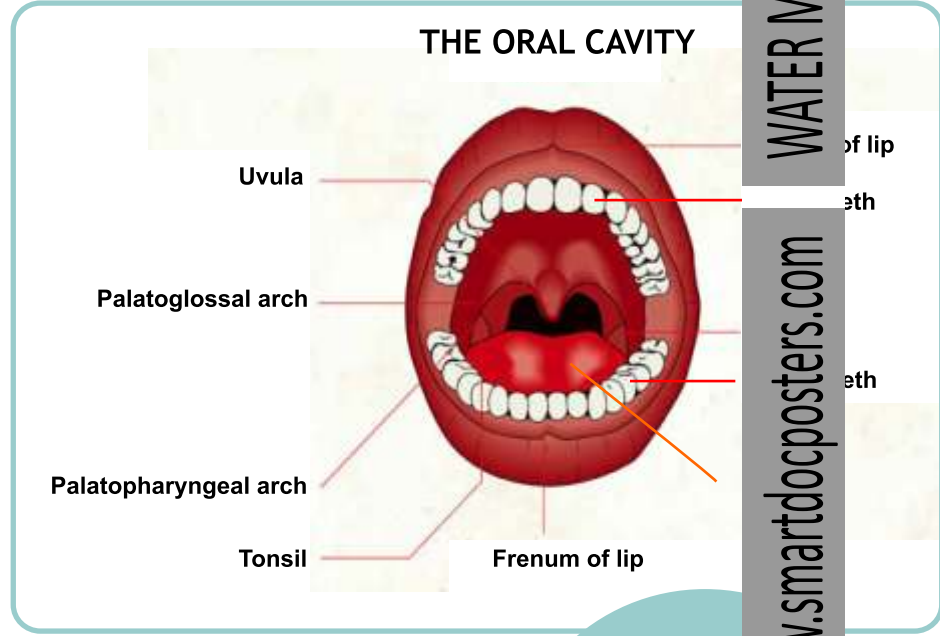
PATIENT EDUCATION

FLIPCHART



SMART DOC®

www.smartdocposters.com

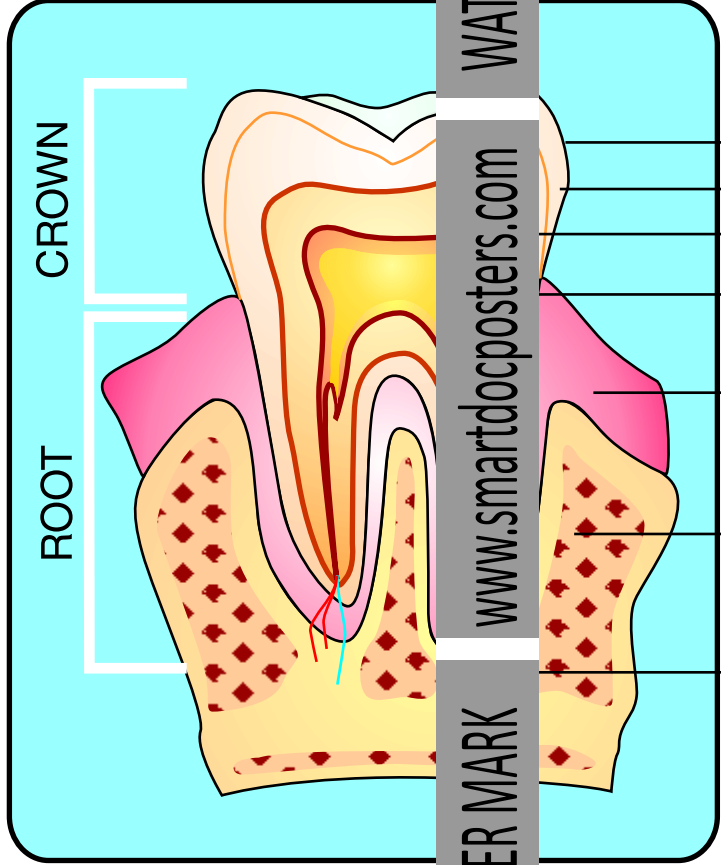


TOOTH - CROSS SECTION

WATER MARK

www.smartdocposters.com

WATER MARK



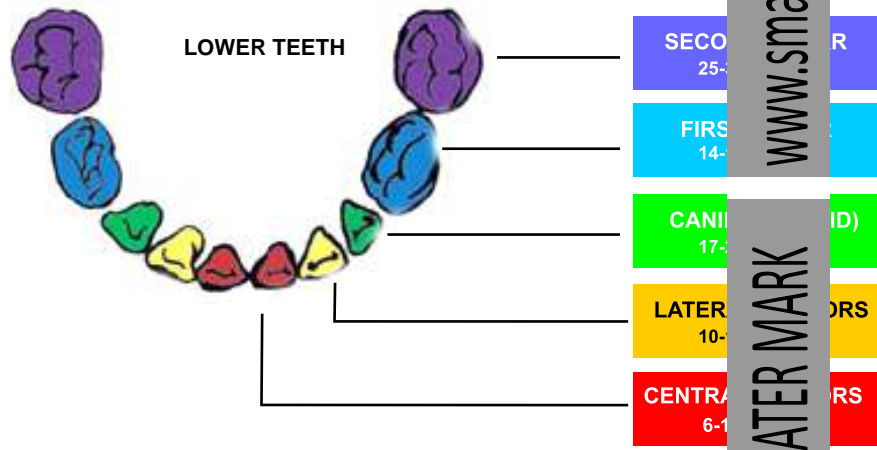
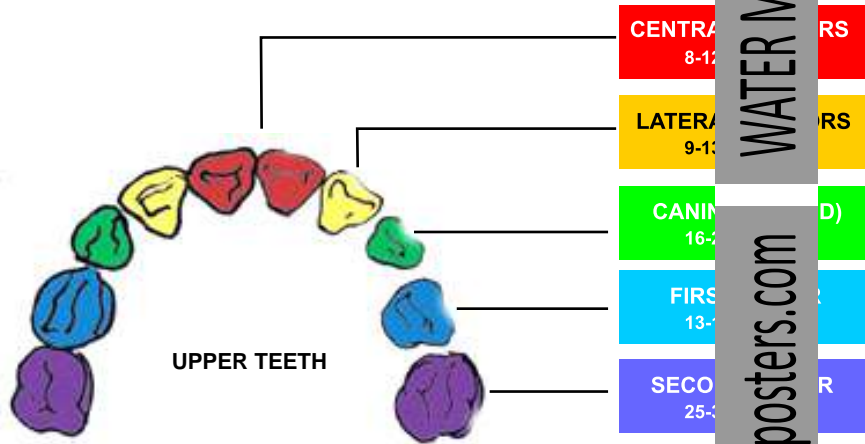
CROWN

ROOT

- Enamel
- Dentine
- Cementum
- Pulp
- Gums
- Alveolar bone
- Blood vessels & nerves

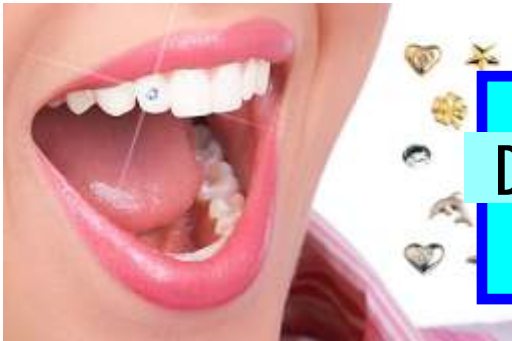TOOTH - CROSS SECTION

PRIMARY TOOTH ERUPTION CHART



WATER MARK www.smartdocposters.com WATER MARK

TOOTH ERUPTION CHART



DENTAL JEWELRY

WATER MARK

www.smartdocposters.com

WATER MARK

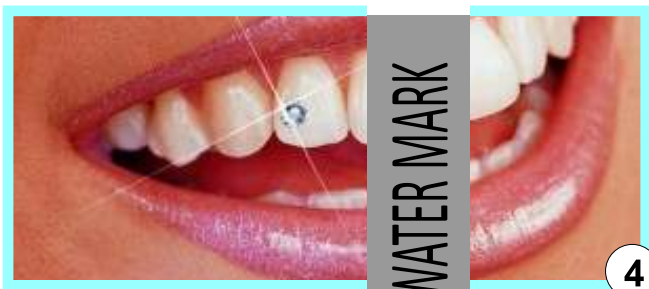
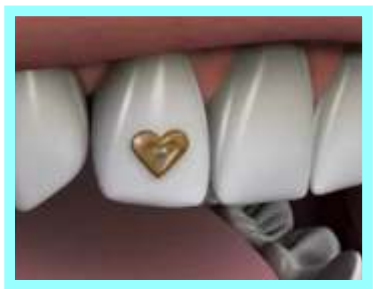A Gem, fixed on anterior tooth

The latest fashion trend !

Fixing Dental Jewelry is a very simple procedure. The Tooth surface is etched and the jewel is placed on the Enamel of the Tooth.

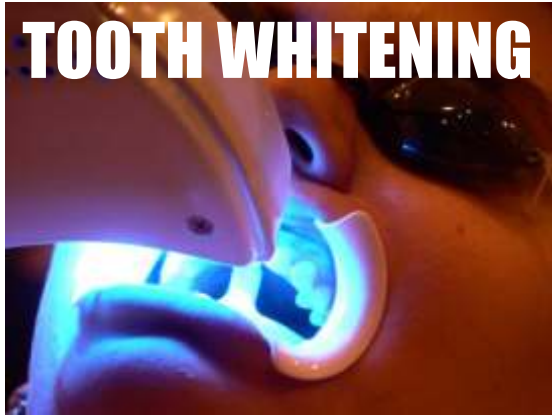It can also be easily removed and the Tooth surface restored with no damage to the Tooth structure!

And is completely affordable



DENTAL JEWELRY

Dental Bleaching (Tooth Whitening) is a common procedure in Cosmetic Dentistry.

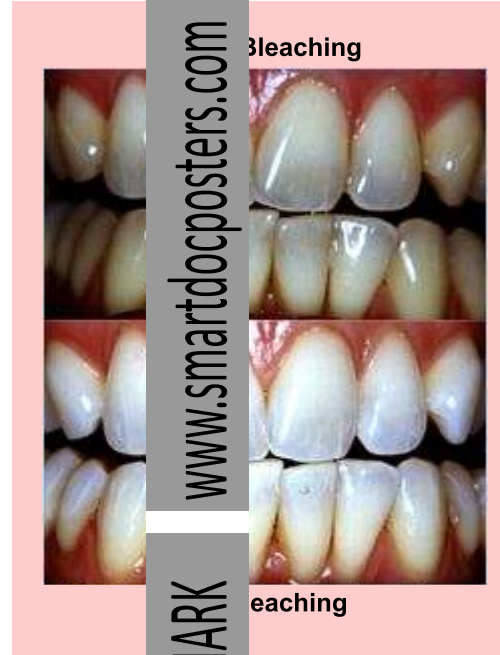

Latest technique of bleaching is...
Laser Bleaching
which uses light energy to accelerate the process of Bleaching

Tooth whitening can be done in approximately 1 hour, in a single visit to the Dentist. (depending on the condition of a person's teeth).

Dental Bleaching

WATER MARK



www.smartdocposters.com

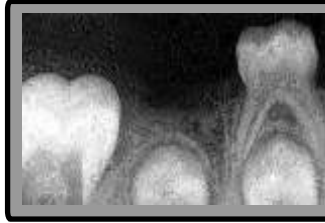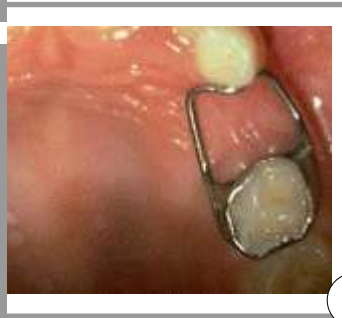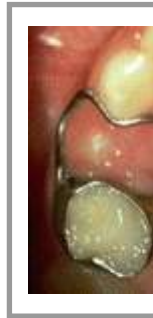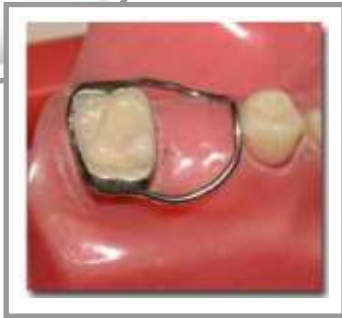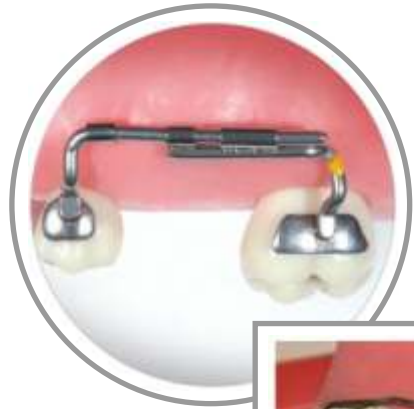WATER MARK

SPACE MAINTAINER

DEVICES

IN CHILDREN

FOR NORMAL ERUPTION OF TEETH



X-ray showing the missing mandibular primary molar. This is a situation requiring placement of a space maintainer, for the proper eruption of the underlying permanent pre-molar tooth.

EARLY LOSS OF primary teeth, causes the permanent teeth to erupt in abnormal pattern !

Later, this condition is corrected only by Orthodontic treatment .

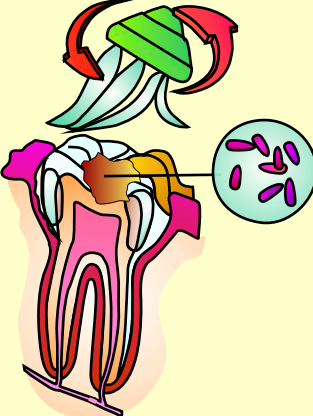
So,...SPACE MAINTAINERS are given, which will preserve the space for the eruption of permanent teeth.

WATER MARK

www.smartdocposters.com

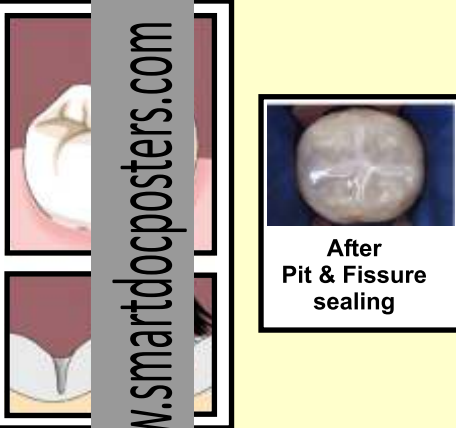
WATER MARK

PREVENT TOOTH DECAY IN CHILDREN BY PIT & FISSURE SEALANTS



DENTAL CARIES

Dental caries occur most commonly in the pits and fissures of Molar tooth, as these areas are difficult to clean.



After Pit & Fissure sealing

The occurrence of caries in children can be prevented by applying Pit and Fissure Sealants

DO REGULAR DENTAL CHECKUP
FOR YOUR CHILDREN
ONCE EVERY 6 MONTHS

WATER MARK
www.smartdocposters.com
WATER MARK

CHILD DENTAL CARE
PIT AND FISSURE SEALANTS

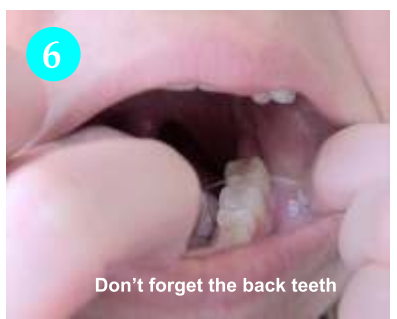
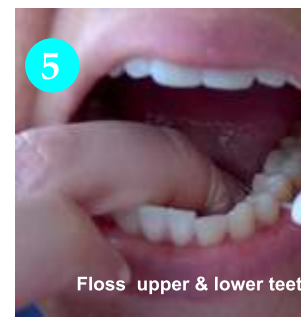
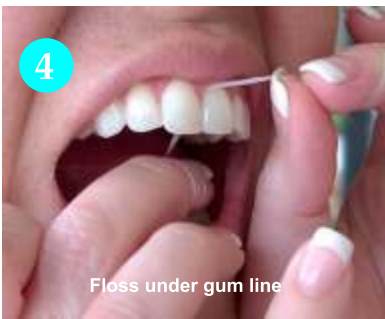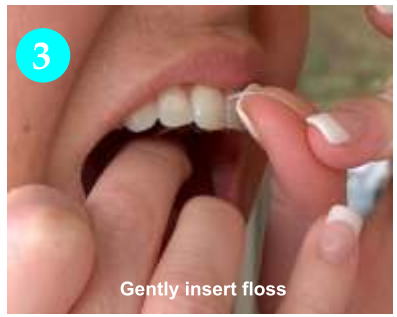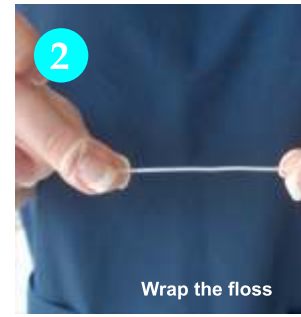
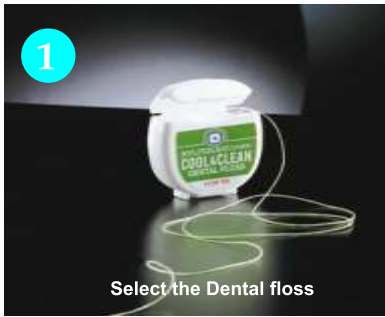Remnants of food particles in between the teeth ,which cannot be removed by brushing must be removed by

DENTAL FLOSSING

WATER MARK

www.smartdocposters.com

WATER MARK



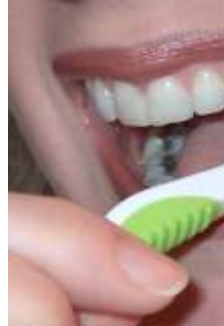Flossing every day
Keeps your Teeth Strong & Healthy

FLOSSING

BRUSHING THE RIGHT TECHNIQUE



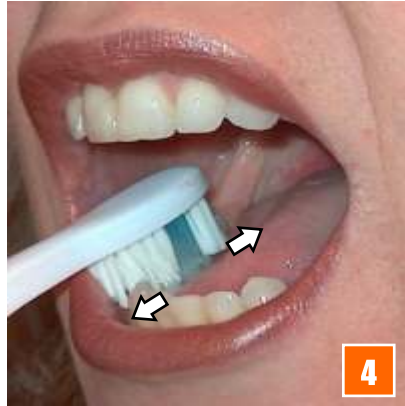
The brush is held with the bristles at a 45 degree angle to the tooth surface, make certain that the bristles are at the gum line.



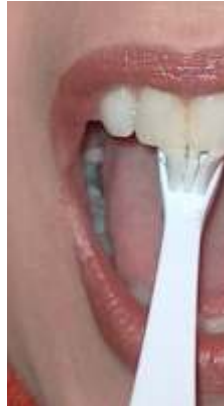Start brushing in a back and forth motion.



The upper teeth is brushed in a downward motion, and the lower teeth in an upward motion.



The chewing surfaces of the teeth are scrubbed, using a short back and forth movement



To clean the inside surfaces of the teeth, tilt the brush vertically and use several gentle up and down strokes using the front half of the brush.



Finally the tongue is also brushed, which will remove the bacteria and freshen your breath...

9

WATER MARK

www.smartdocposters.com

WATER MARK

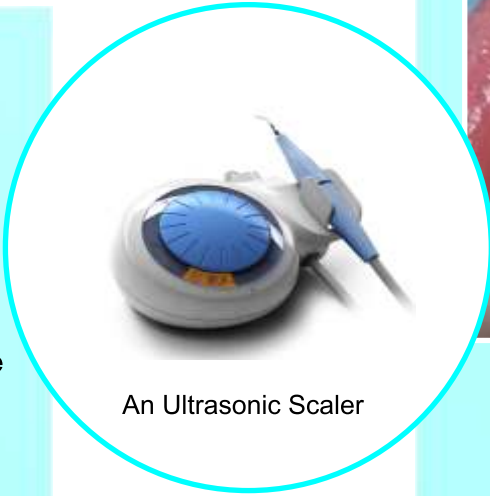
BRUSHING

SCALING

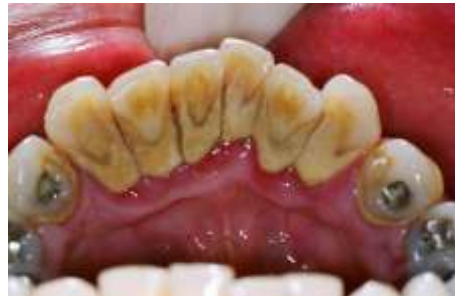Scaling (Professional cleaning of teeth) is a ...
Painless Procedure,

Done with the help of an
Ultrasonic Cleaning Device.

The procedure removes the
Calculus deposits (CALCIFIED PLAQUE AND TARTAR DEPOSITS) & stains That cannot be removed by brushing .

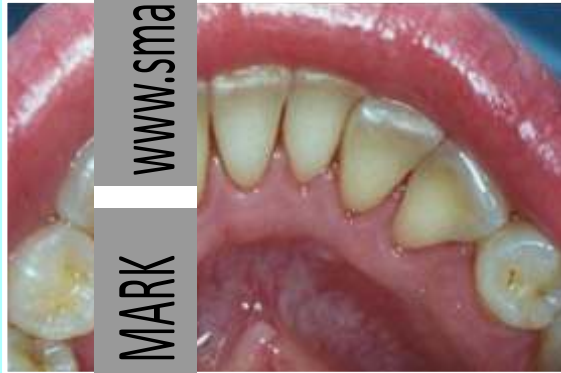

An Ultrasonic Scaler

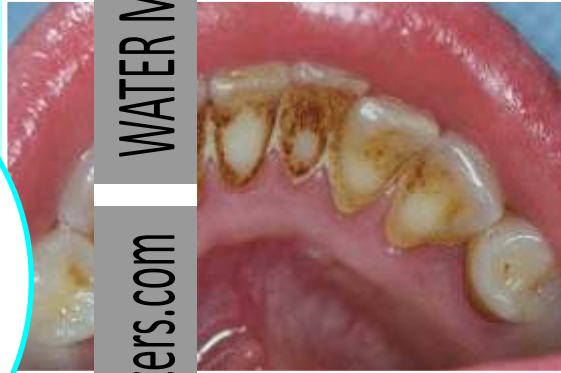

Calculus deposits

SCALING
SHOULD BE DONE
ONCE IN 6 MONTHS



After Cleaning



Before Cleaning

The deposits covered by calculus deposits and stains

WATER MARK

www.smartdocposters.com

WATER MARK

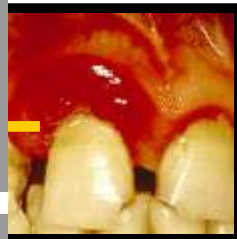If the Dental calculus accumulating on teeth is not removed by scaling (ultrasonic teeth cleaning), It can lead to...

GUM DISEASE

Progression of GUM DISEASE if untreated ...

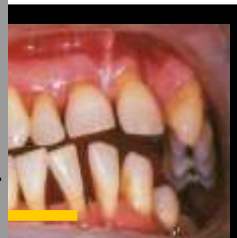
Early stages of gum disease

- Painless
- Gums are red and swollen
- Bleeding while brushing
- Bad breath arises.



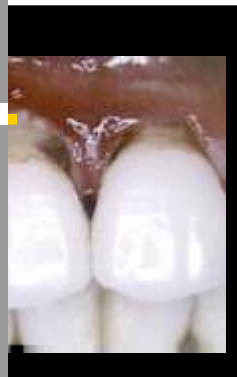
Second stage

- The gum margins become detached from the tooth surface and a pocket (periodontal pocket) forms between the tooth and gums.
- Exposure of the tooth root.
- Sensitivity and pain occurs.



Third stage

- BONE DESTRUCTION occurs at this stage.
- The **TOOTH IS LOOSE!**



TREATMENT at each stages

- Brushing and flossing
- Calculus removal by ultrasonic teeth cleaning (scaling)
- Proper medications

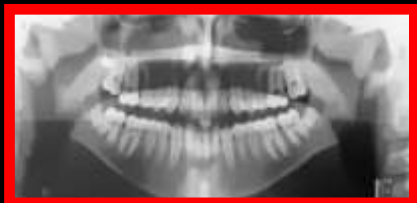
- Brushing and flossing
- Sub gingival Calculus removal by ultrasonic teeth cleaning (scaling)
- Proper medications
- Gum surgery (Periodontal flap surgery)

Extraction of tooth
May be the only option!

WATER MARK

www.smartdocposters.com

WATER MARK



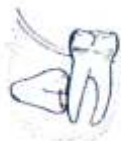Impaction

Types of Impacted Tooth

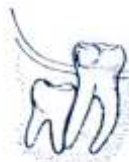WATER MARK

www.smartdocposters.com

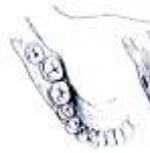WATER MARK



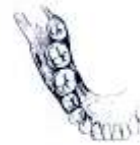Horizontal



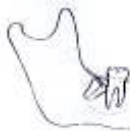Vertical



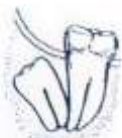Bucco -version



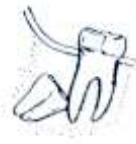linguo version



Mesio-angular



Disto - angular



Lowlevel



High level

The majority of the tooth portion remains embedded (Impacted) in the Mandibular Bone (Lower jaw bone). Removal of an Impacted tooth requires much more effort than a normal tooth extraction and also requires much care (after it...)



WATER MARK

Care After Tooth Removal

1

Bite gently, but firmly
on the cotton gauze.

This will control
bleeding.

Remove it after 45
minutes.

www.smartdocposters.com

Placing an
Ice Pack
on the cheek
will control bleeding
and reduce swelling.

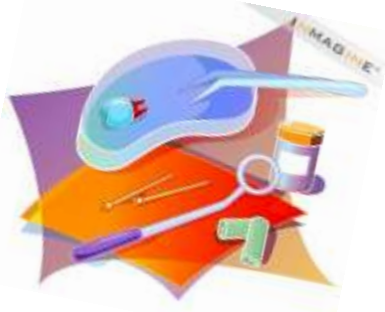WATER MARK

Avoid hard work, &
Sports, first 24 hours
after extraction.



13

CARE AFTER EXTRACTION



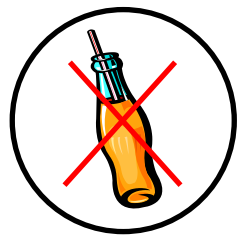WATER MARK

Care After Tooth Removal

www.smartdocposters.com



Avoid hot, sticky, & hard foods.



Do not use straw.



Take soft cold food

Gargle mildly with luke warm salt water 8 hrs. after extraction..

Do so for 3 days.

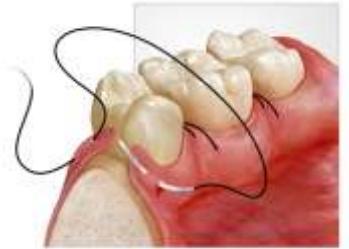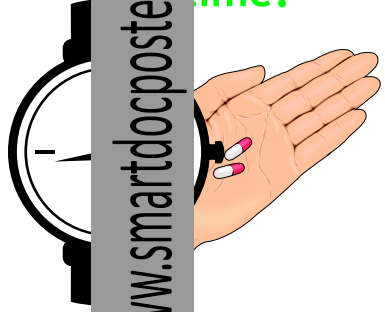
WATER MARK

Care After Tooth Removal

**No Smoking .
No Alcohol.**
after
extraction and
during the
time of
Medication.



**Take the prescribed
Medicines at the Right
dosage at the Right
time.**



If there is a suture at the
extraction site, get it
removed at the next
appointment itself, as
advised by your Doctor.

Consult your Doctor if there is...

Severe Pain after the day of extraction.

Uncontrolled bleeding or Swelling.

Rashes, Itches, Swelling, or Irritation of the eye after taking Medicines.

WATER MARK

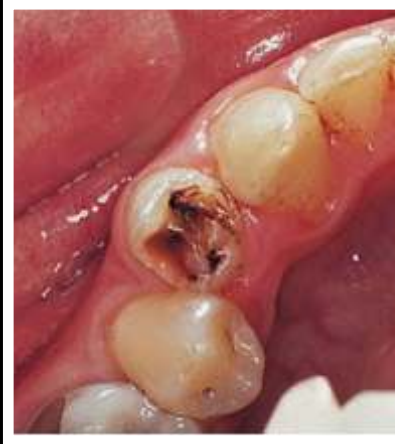www.smartdocposters.com

WATER MARK

Even badly decayed tooth can be saved by

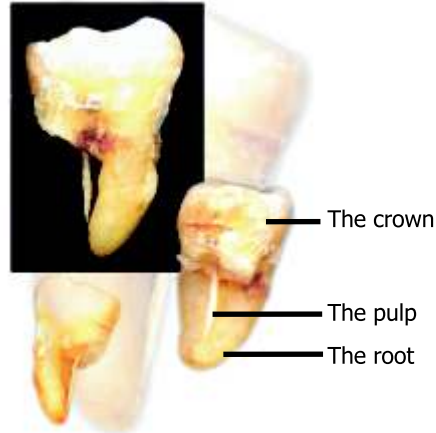
ROOT CANAL TREATMENT

The process involves, removing the infected Pulp, and filling of the tooth from the root tip.



A badly decayed tooth

The Dental Pulp



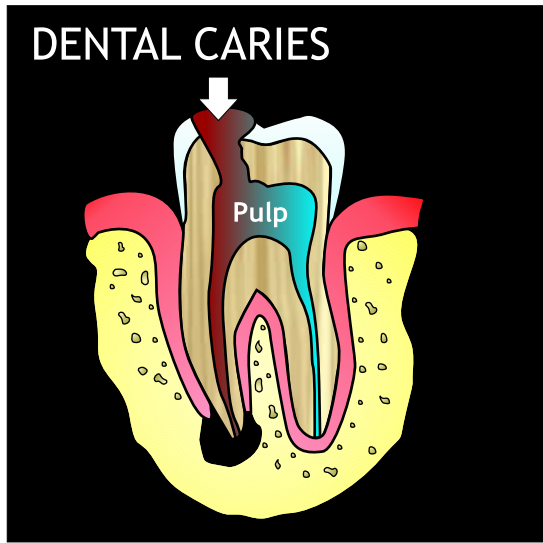
ROOT CANAL TREATMENT PROCEDURE

DIFFERENT STAGES


WATER MARK

www.smartdocposters.com

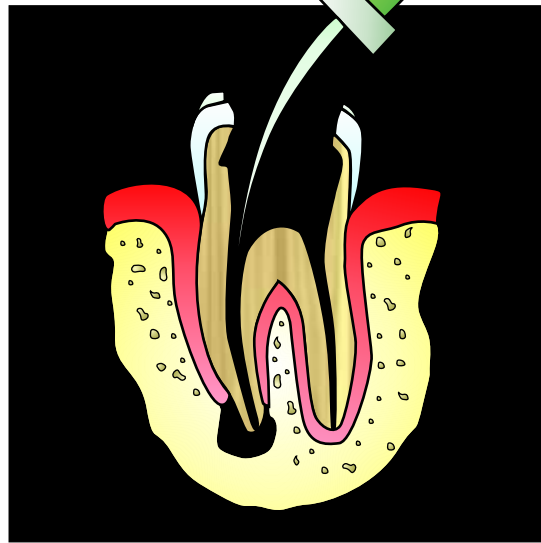WATER MARK



Dental Caries involving the Pulp.



Access to root canal is prepared using Reamer Instrument.



The damaged pulp is removed using endodontic instruments and the root canal is cleaned.



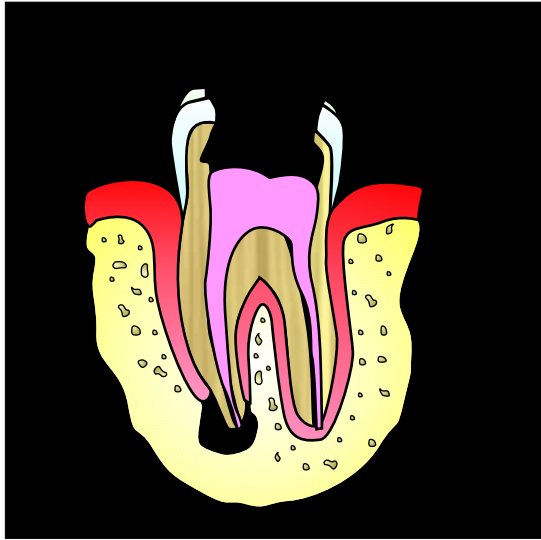
ROOT CANAL TREATMENT PROCEDURE

DIFFERENT STAGES

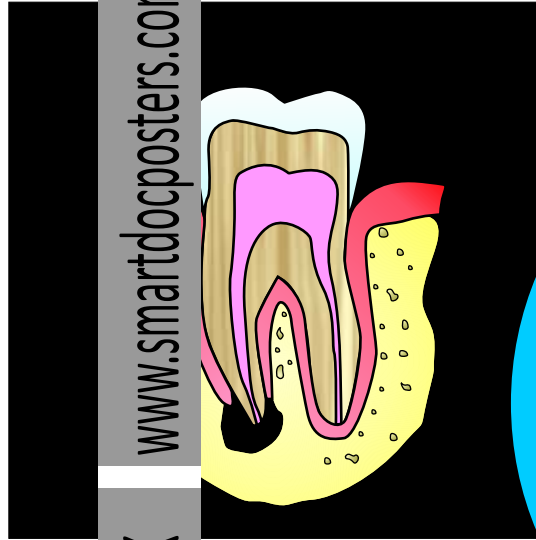
WATER MARK

www.smartdocposters.com

WATER MARK

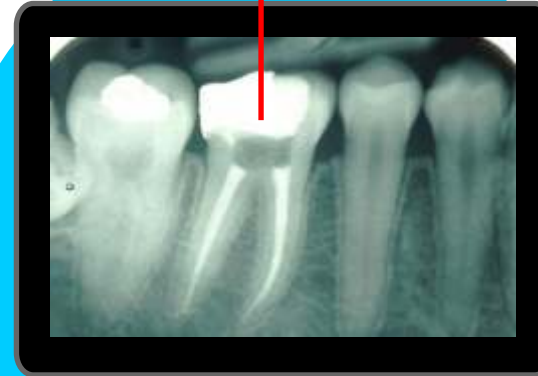

The canal is then filled with an inert material called GUTTA - PERCHA.



After the root canal procedure, the tooth is capped.

GUTTA -PERCHA Filling



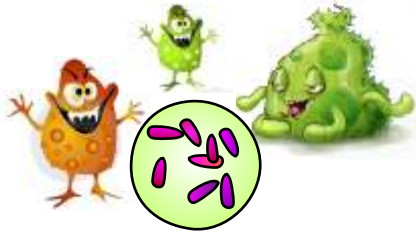
A Dental X-ray taken after Root Canal Treatment procedure

3

18

ROOT CANAL TREATMENT

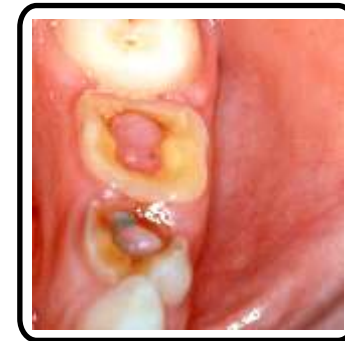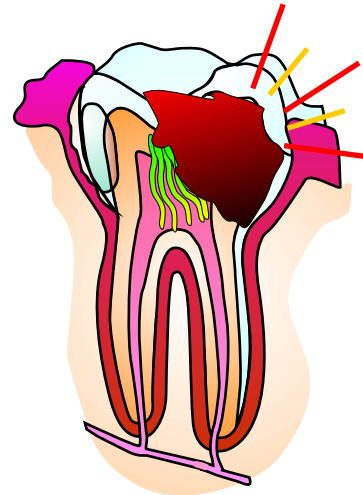
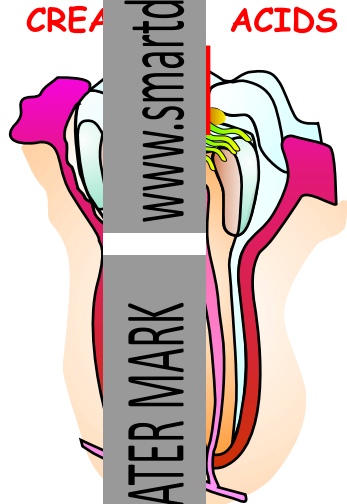
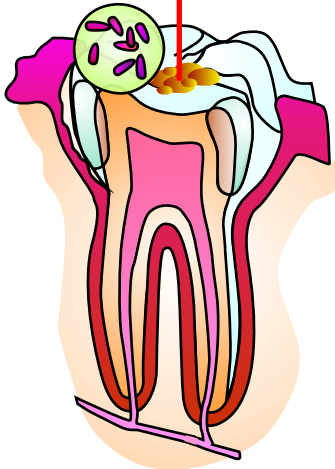
HOW CARIES OCCUR ?



THE ORAL BACTERIA



ACTS ON FOOD DEBRIS
REMAINING ON TOOTH
DUE TO IMPROPER BRUSHING



WATER MARK

www.smartdocposters.com

WATER MARK

DENTAL CARIES

Caries is the most common
Dental problem

THESE ACIDS CORRODE
THE TOOTH STRUCTURE
CAUSING..
DENTAL CARIES !

DENTAL CARIES

DENTAL CARIES

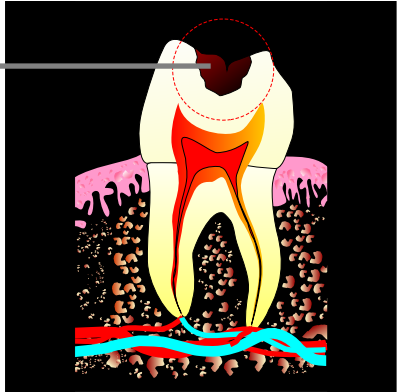
If left untreated...

WATER MARK

www.smartdocposters.com

WATER MARK


CARIES OF THE ENAMEL & DENTINE



At this stage,
The Tooth can be filled and saved !



CARIES SPREADS TO THE PULP



At this stage,
Treatment can be done
and, ..
Tooth be saved !



CARIES LEADING TO ACCESS !

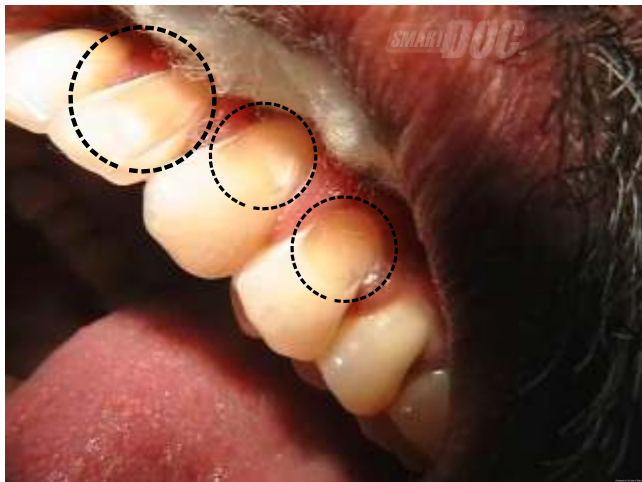


GAME OVER !
Sevre pain and swelling
The Tooth is to be removed !

ONE OF THE MAIN CAUSES FOR SENSITIVE TEETH



ABRASION OF ENAMEL



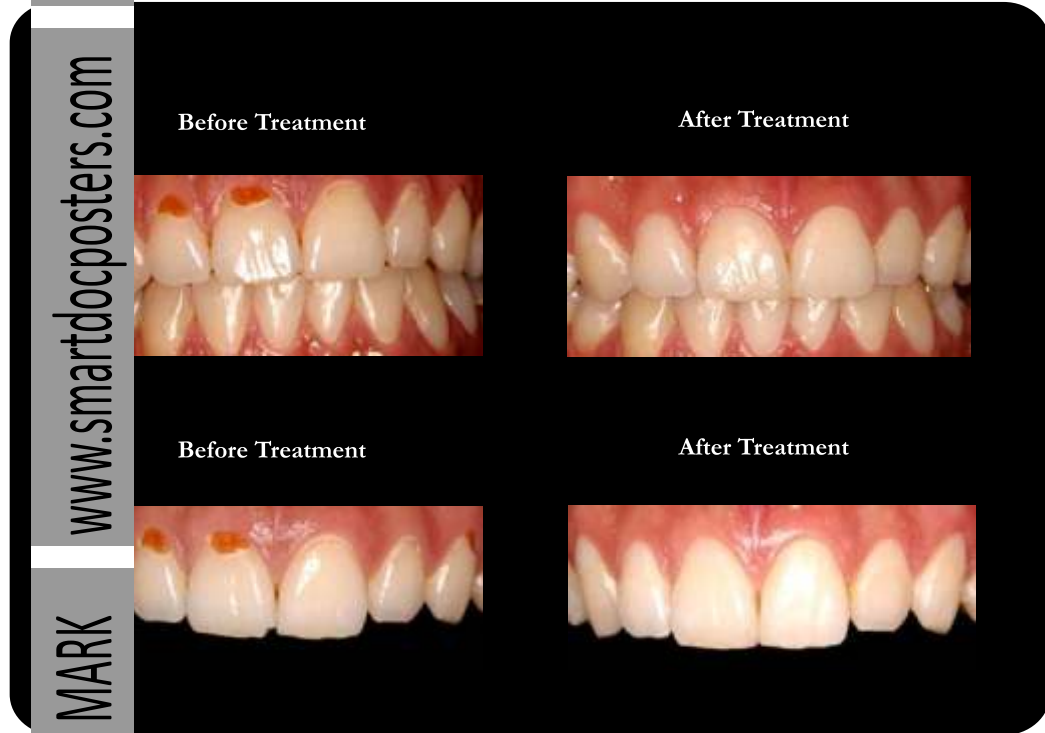**ABRASION OF THE ENAMEL
IF LEFT UNTREATED
CAN LEAD TO LOSS OF TEETH !**



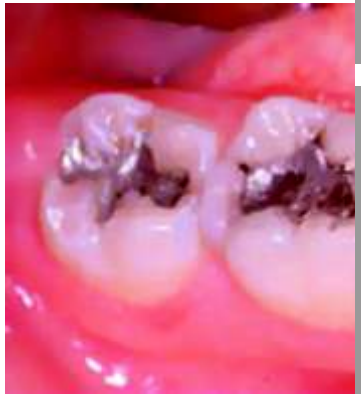TOOTH COLOURED COMPOSITE FILLINGS

This can be corrected by
Rebuilding the Abrased Part with ...

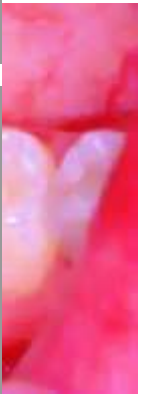
WATER MARK
www.smartdocposters.com
WATER MARK



Old, Metallic Veneer fillings can be replaced with TOOTH COLOURED COMPOSITE FILLINGS

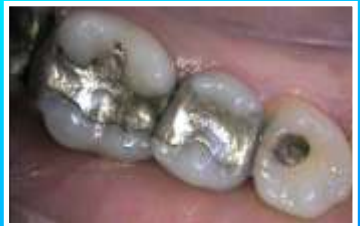

Visible Metallic fillings



The teeth refilled using composites

WATER MARK www.smartdocposters.com WATER MARK



Why old Amalgam Fillings be replaced ?

As Amalgam fillings have Metallic properties,they expand and contract when eating hot and cold food. This causes micro-leakage between fillings and the tooth,through which seepage of materials occur. This may cause decay and in due course affects the Pulp,..resulting in severe infection and pain.

Moreover the metallic fillings are visible,and it affects your appearance

**VISIBLE Fillings
made
INVISIBLE !**

Broken tooth Can be repaired !

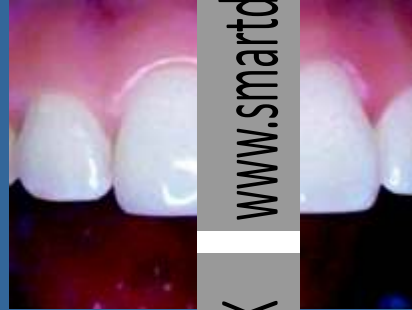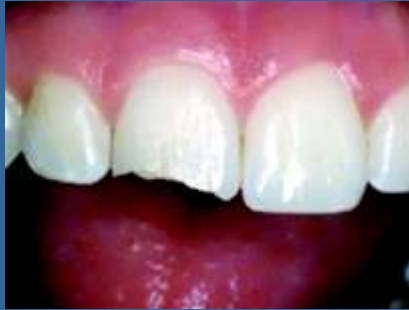With...

TOOTH COLOURED COMPOSITE FILLINGS

Before Treatment

After Treatment

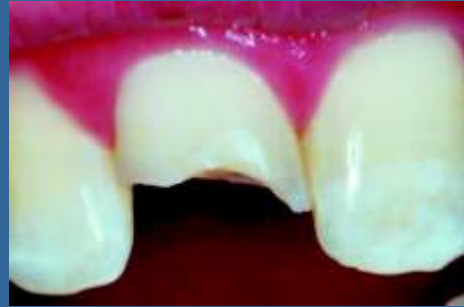Case-1



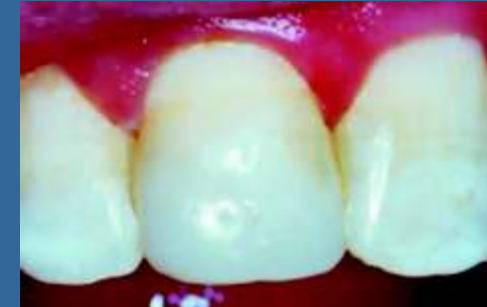Before Treatment

After Treatment

Case-2



A broken front tooth

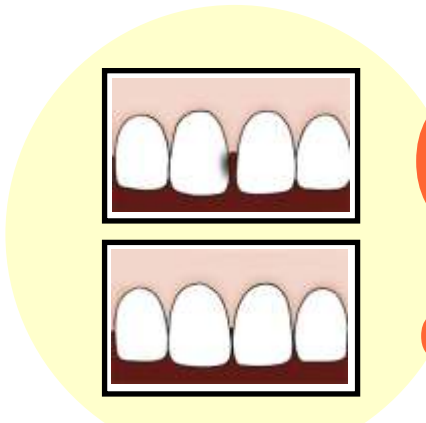


The broken tooth reconstructed using composite, within minutes

WATER MARK

www.smartdocposters.com

WATER MARK



GAPS

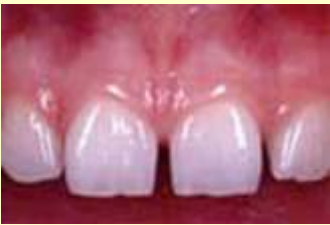BETWEEN TEETH
CAN BE CLOSED

TOOTH COLOURED COMPOSITE FILLINGS !

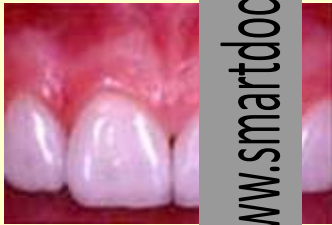WATER MARK

www.smartdocposters.com

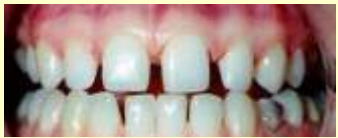WATER MARK



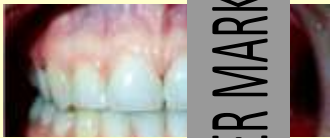
BEFORE



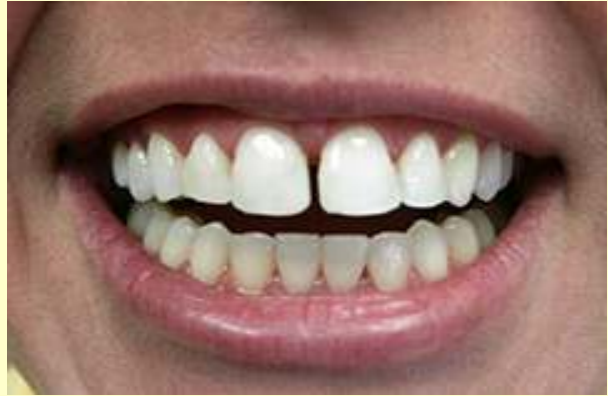AFTER



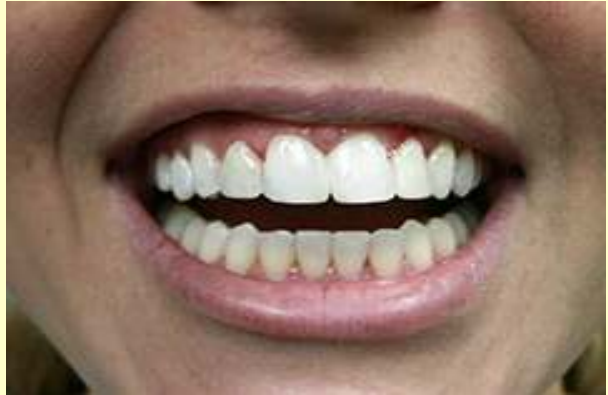BEFORE



AFTER



BEFORE




AFTER

WHY REPLACE MISSING TEETH

1

Difficulty in CHEWING

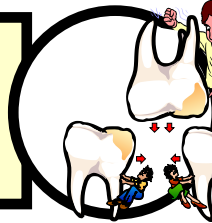
↓
Improper chewing
causes
Indigestion & Gastric Problems...



2

Remaining Teeth drift to Extracted tooth area...


↓
Causing Mobility of other teeth!



3

Older Appearance to Face !

↓
Cheeks shrink inside to the extracted area
giving an older appearance to the face!



4

Difficulty in SPEECH

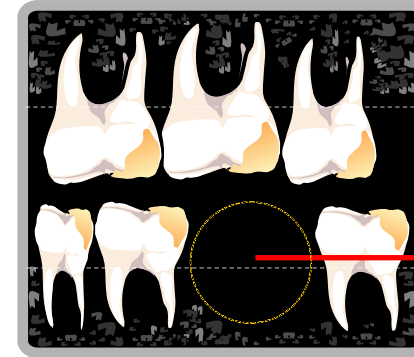


WATER MARK

www.smartdocposters.com

WATER MARK

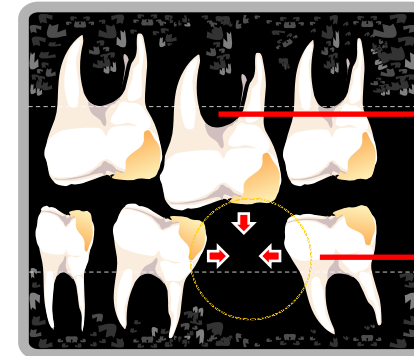
How Missing teeth causes MOBILITY OF OTHER TEETH !!!



Gum Line

Extracted Tooth area

After a few months....



Upper teeth drifts down to the space !
The Root is exposed !
Causing ...

**Mobility !
Severe Sensitivity !
& Pain !!**

Adjacent teeth shifts to that
space.
**Both teeth becomes
mobile !**

If a lower teeth is Extracted ,and not replaced within 2 weeks,...
You will loose
another 3 Teeth in the future !

1

25

DENTURES

THE MOST PERFECT WAY TO REPLACE MISSING TOOTH PERMANENTLY !

CERAMIC FIXED DENTURES



How are they fixed ?

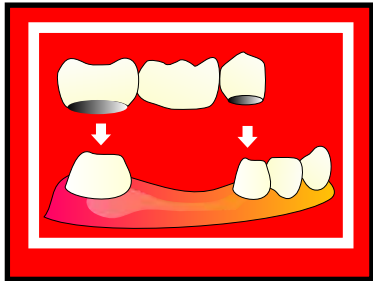
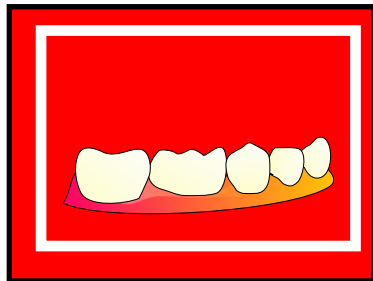


Diagram showing crown and bridge Fixed Denture placement on missing tooth area.

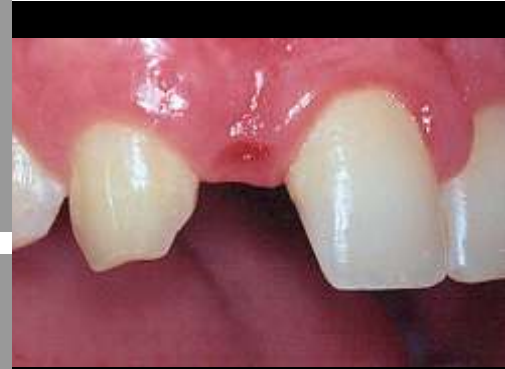

The Dentures, once fixed cannot be removed by the patient.

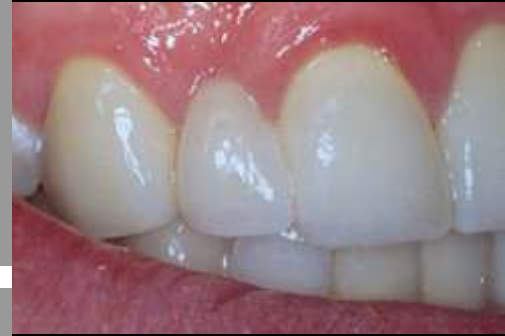WATER MARK

www.smartdocposters.com

WATER MARK



Missing tooth area



After ceramic denture replacement !

TYPES OF REMOVABLE DENTURES

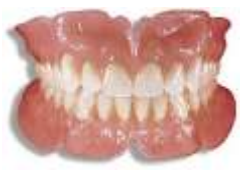WATER MARK

www.smartdocposters.com

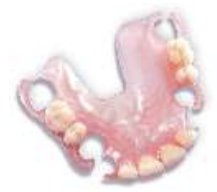WATER MARK

1

ACRYLIC DENTURES



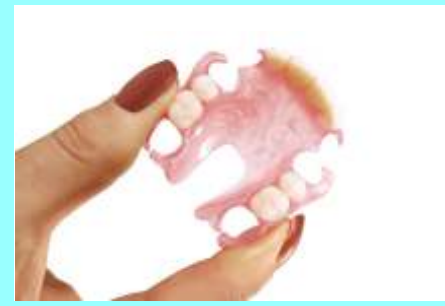Upper & Lower Full Denture



Partial Denture

3

FLEXIBLE DENTURES



Light weight & Flexible !

No visible clasps

Unbreakable & durable

4

PRECISION ATTACHMENT DENTURES

EXTRA CORONAL ATTACHMENT



To this extra coronal attachment the Removable acrylic Denture is fixed.

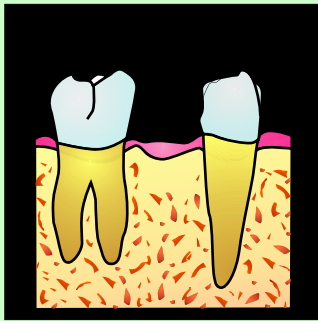


IMPLANTS

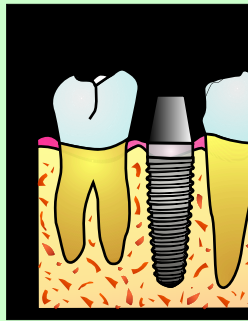
FIXED DENTURES

The most advanced technology
in Fixed Denture Replacement !

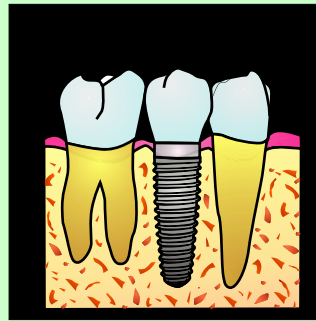
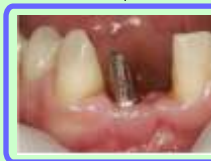Titanium Screws are surgically placed into the Alveolar bone.
These screws have extensions (Abutments) in the oral cavity,
on to which the Artificial Teeth are fixed !



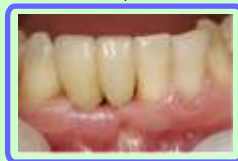Missing Tooth area



Titanium Screw is placed surgically in the



Artificial teeth is fixed on to the Titanium Screw

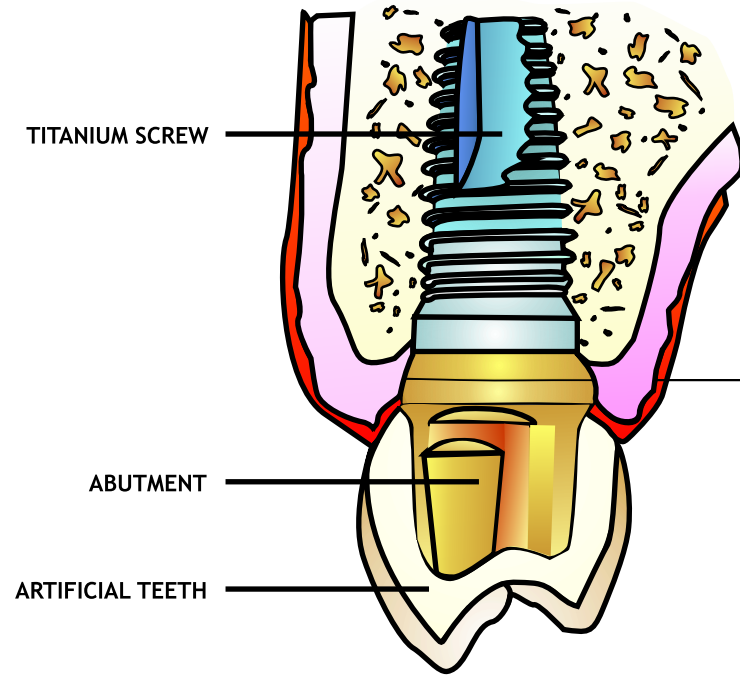


WATER MARK

www.smartdocposters.com

WATER MARK

PARTS OF A DENTAL IMPLANT



Orthodontic Treatment

The need for **ORTHODONTIC Treatment**

Mal occlusion(improper teeth alignment) may lead to the following problems...

1

Poor facial appearance

Malocclusion adversely affects the facial appearance of an individual.

2

Risk of caries

Mal-aligned teeth makes oral hygiene maintenance difficult, thereby increasing the risk of dental caries occurrence.

3

Periodontal diseases

Mal occlusion causes poor oral hygiene which initiates periodontal disease.

4

Psychological disturbances

As mal occlusion adversely affects the appearance of the individual, it may cause psychological disturbances .

5

Risk of trauma

Proclined teeth are always prone to risk of fracture, during play or accidents.

6

Abnormalities of function

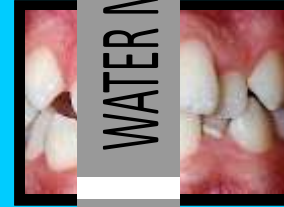
Mal occluded teeth causes functional disturbances like-improper chewing, speech defects, breathing problems etc.

7

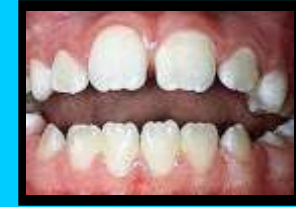Temporo-mandibular joint problems

Mal occluded teeth causes Temporo-mandibular joint pain and dysfunction.

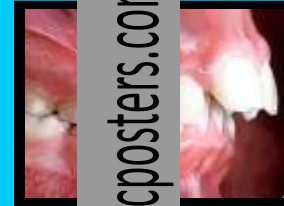
Common Orthodontic Cases



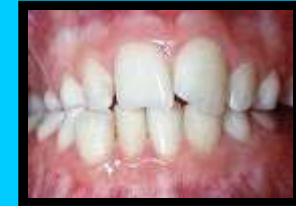Teeth



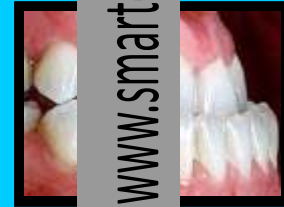Open Bite



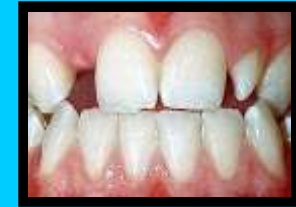Teeth



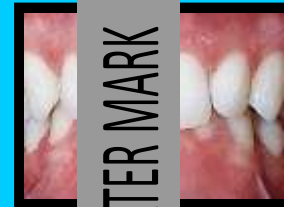Cross Bite



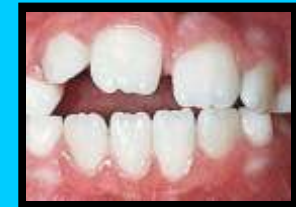Lower front teeth beyond upper teeth.



Missing Teeth



Upper front lower teeth



Thumb Sucking

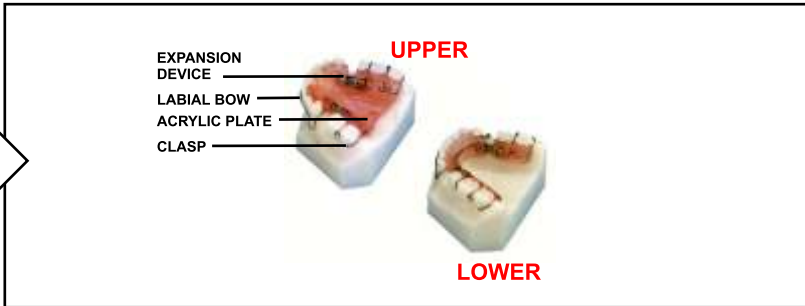
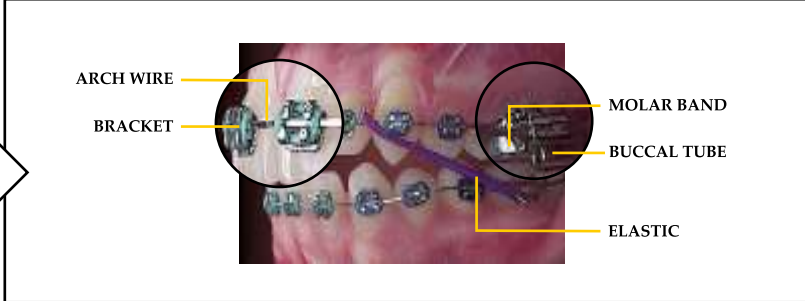
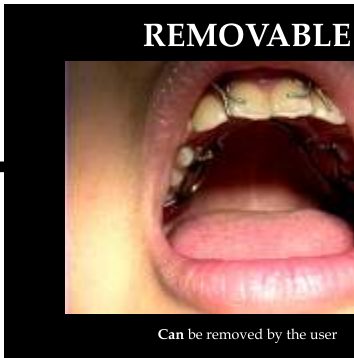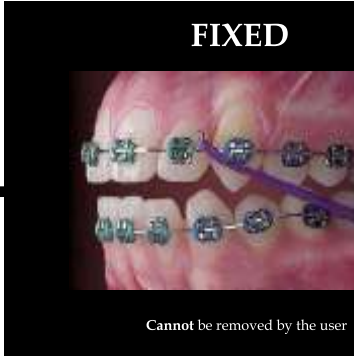Orthodontic Treatment aims at diagnosis,Prevention and Treatment of Dental mal allignme and Facial Irregularities ...

WATER MARK

www.smartdocposters.com

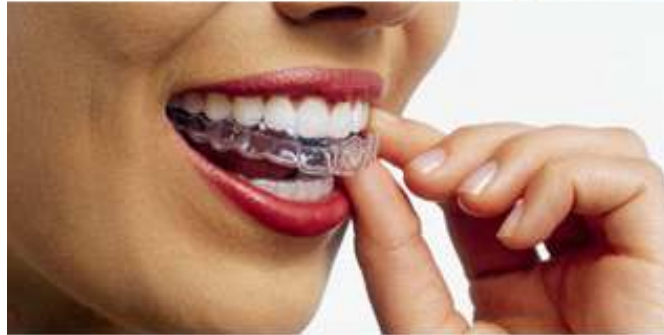WATER MARK

Main types of ORTHODONTIC TREATMENT



TYPES OF BRACES

<p>Steel Braces</p>	<p>Ceramic Braces</p>
<p>Colour Braces</p>	<p>Invisible Braces or lingual braces</p>



Invis Align

Invis align is a method of orthodontic treatment which uses a series of **CLEAR, REMOVABLE TEETH ALIGNERS**

Used as an alternative to traditional metal dental braces.



WATER MARK

www.smartdocposters.com

WATER MARK

Advantages

The aligners are **COMPLETELY TRANSPARENT** they are almost invisible when compared to traditional wire and bracket braces. So they are preferred due to cosmetic reasons.

The aligners are **MORE COMFORTABLE** than metallic braces.

The device is **REMOVABLE**, food consumption is easier than with metallic braces.

Invis align treatment have been claimed to have **BETTER RESULTS** than traditional orthodontics.

Disadvantages

The success of the Invis aligners is based on the patient's commitment to wear the aligners (for a minimum of 20-22 hours per day).

If the patients fail to keep the aligners in for the required length of time, then the next aligner in the series will not fit, and a new set of impressions and aligners will be necessary, adding to the cost.

As the aligners are removed for eating, there are chances of losing them.

The system is more expensive than traditional wire and bracket systems.

MYO-FUNCTIONAL Appliances

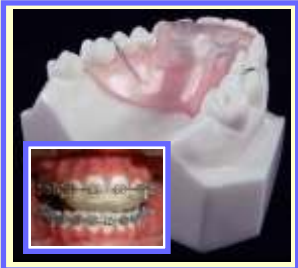In some cases, Orthodontic treatment procedure may include the use of Myo-functional appliances.

These appliances depend on Oro-facial muscles & soft tissues for their action.

WATER MARK

www.smartdocposters.com

WATER MARK



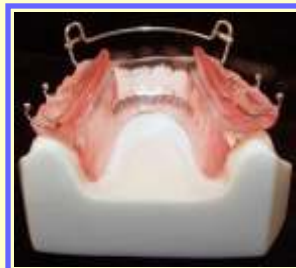BITE PLANE



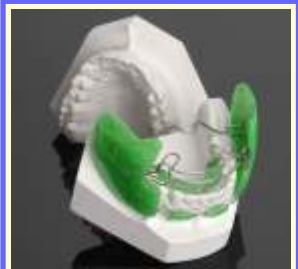VESTIBULAR SCREEN



LIP



ACTIVATOR



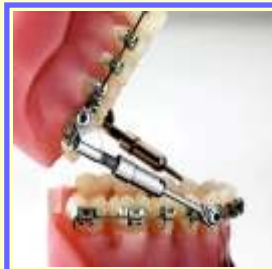FRANKEL APPLIANCE



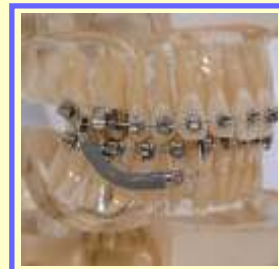BIONATOR



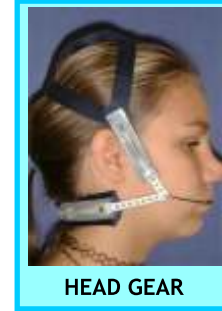TWIN BLOCK APPLIANCE



HERBST APPLIANCE

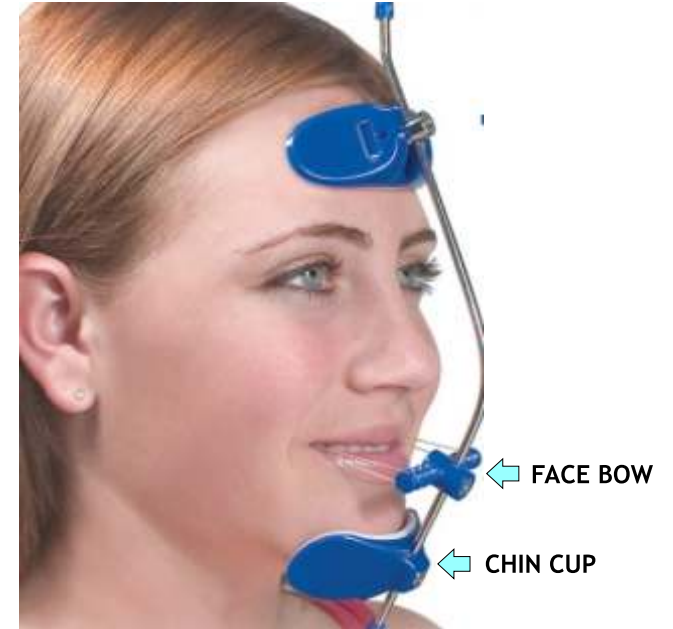

JASPER JUMPER



HEAD GEAR

ORTHOPAEDIC Appliances



FACE MASK